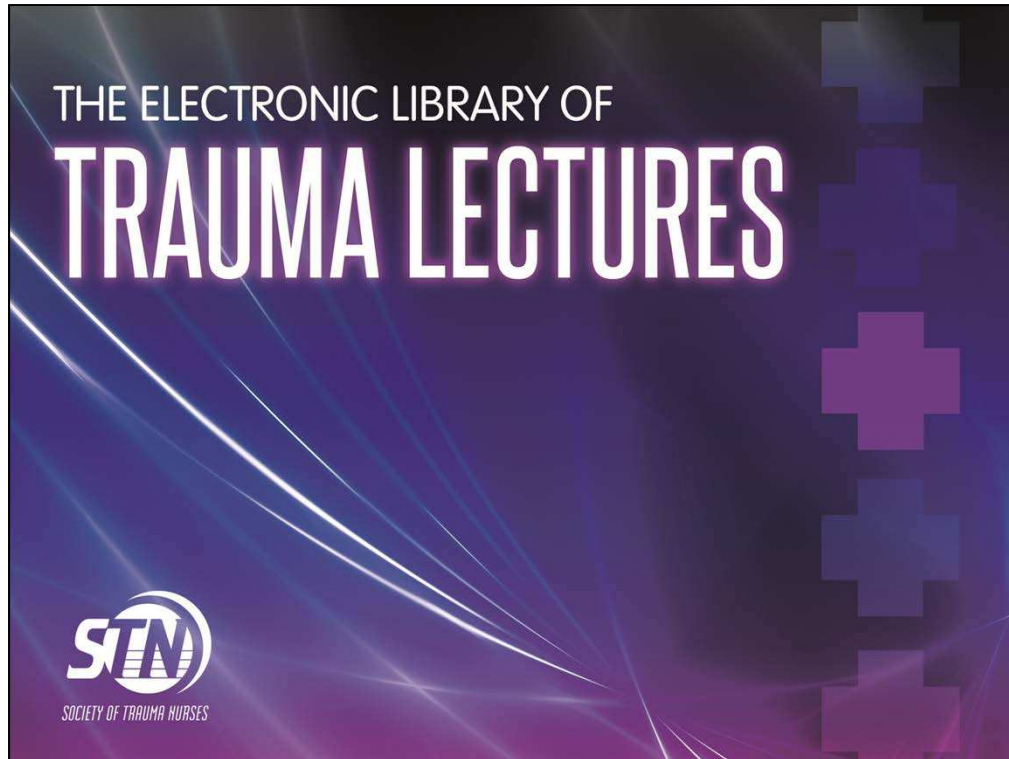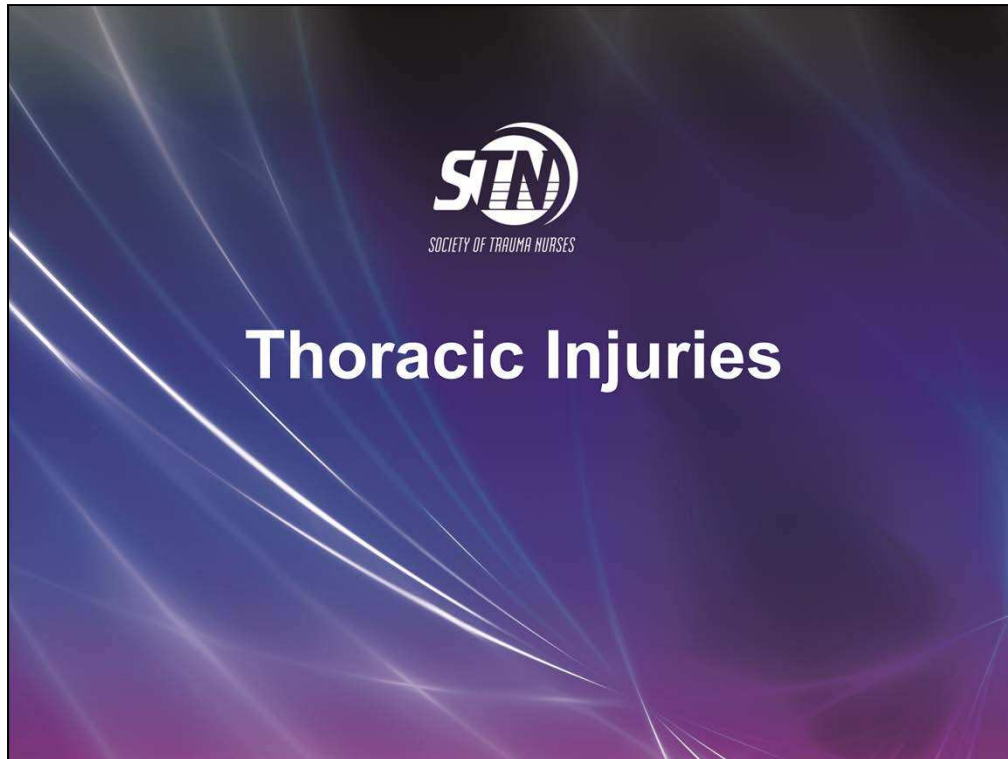


Chest injuries remain a significant cause of morbidity and mortality



Objectives

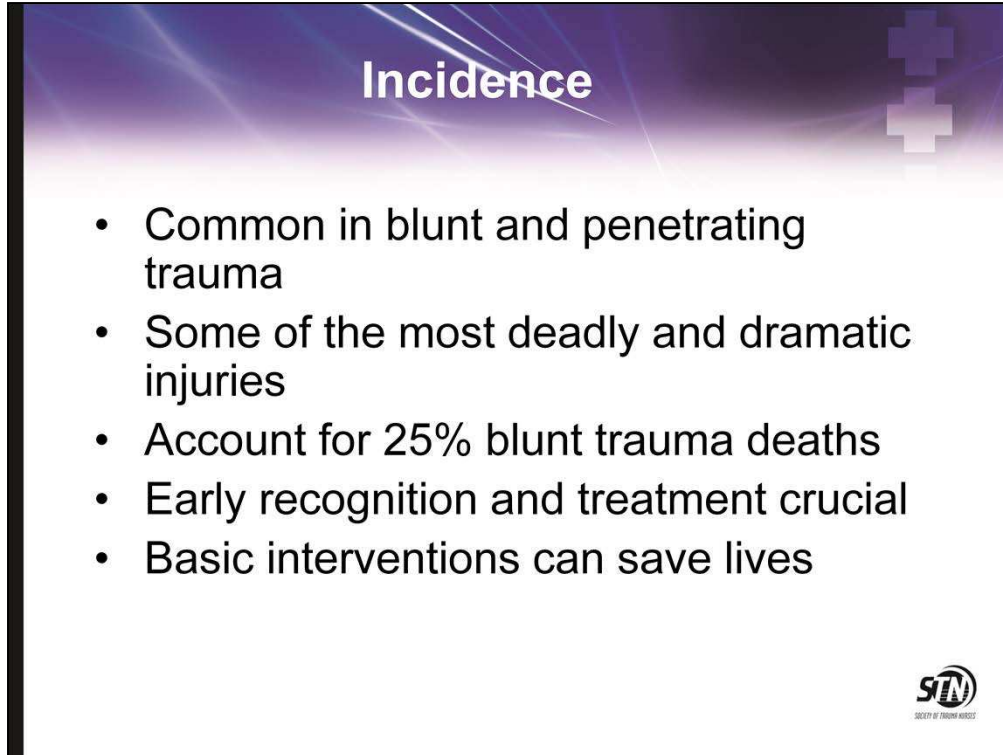
**At the conclusion of this presentation
the participant will be able to:**

- Describe resuscitative interventions for patients with thoracic trauma
- Explain clinical manifestations associated with life-threatening injuries
- List life-threatening injuries that should be identified during the primary survey
- Identify general treatment for patients with thoracic trauma



There are many vital structures located within the chest cavity, too numerous to review in detail.

The purpose of this presentation is to provide an overview of major injuries in the thorax and some of the early interventions associated with their management.



Incidence

- Common in blunt and penetrating trauma
- Some of the most deadly and dramatic injuries
- Account for 25% blunt trauma deaths
- Early recognition and treatment crucial
- Basic interventions can save lives

STN
SOCIETY OF THORACIC SURGEONS

Many cases of traumatic deaths due to chest injury may be prevented by prompt diagnosis and a standardized therapeutic approach in the trauma resuscitation room. A high index of suspicion for lethal injury patterns, based on the mechanism of trauma and the clinical presentation, is a crucial to prompt diagnosis and intervention.


These injuries may be quite subtle in their presentation or they manifest through a very dramatic presentation with profound physiologic derangements leading to death within minutes if not corrected.

- Immediate deaths from blunt chest trauma usually related to heart or thoracic aorta disruption
- Death within 3 hours of injury related to airway obstruction, cardiac tamponade, aortic disruption, or continued hemorrhage
- Late deaths from blunt chest trauma usually due to missed injuries, multiorgan system failure, systemic inflammatory response syndrome, respiratory complications, and infections
- Many injuries are managed nonoperatively
- About 85% of patients with thoracic injuries only require a chest tube, observation, and pain management

Trauma, 6th Edition, Indications for and Techniques of Thoracotomy, pg 512.

Keep It Simple

- Penetrating versus blunt
- Airway, breathing, circulation
- Hemodynamically stable versus unstable
- Identify immediately lethal injuries



BLUNT

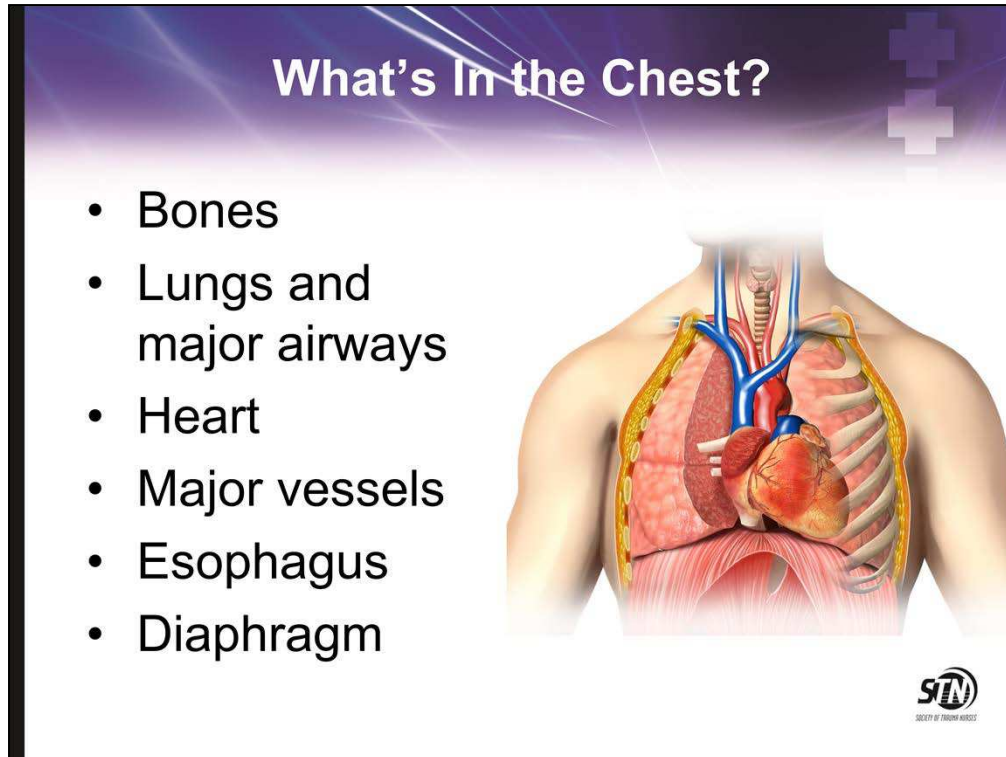
- Injury is dependent upon direction, intensity, and application of force
- Forces distributed over large area

PENETRATING

- Damage is proportional to the energy by the object
- Blast injury related to characteristics of wave
- Organs injured usually those that lie along path of penetrating object
- Keep in mind the entry point of the bullet may not be in an external thoracic location. It may be the trajectory that causes an injury to a structure within the chest cavity.
- The entry point of a knife may be posterior but still enter the thoracic cavity as in the picture above. Consider length of blade.
- Remember: impaled objects should never be moved until controlled circumstances exist, preferably in the OR.

Initial management

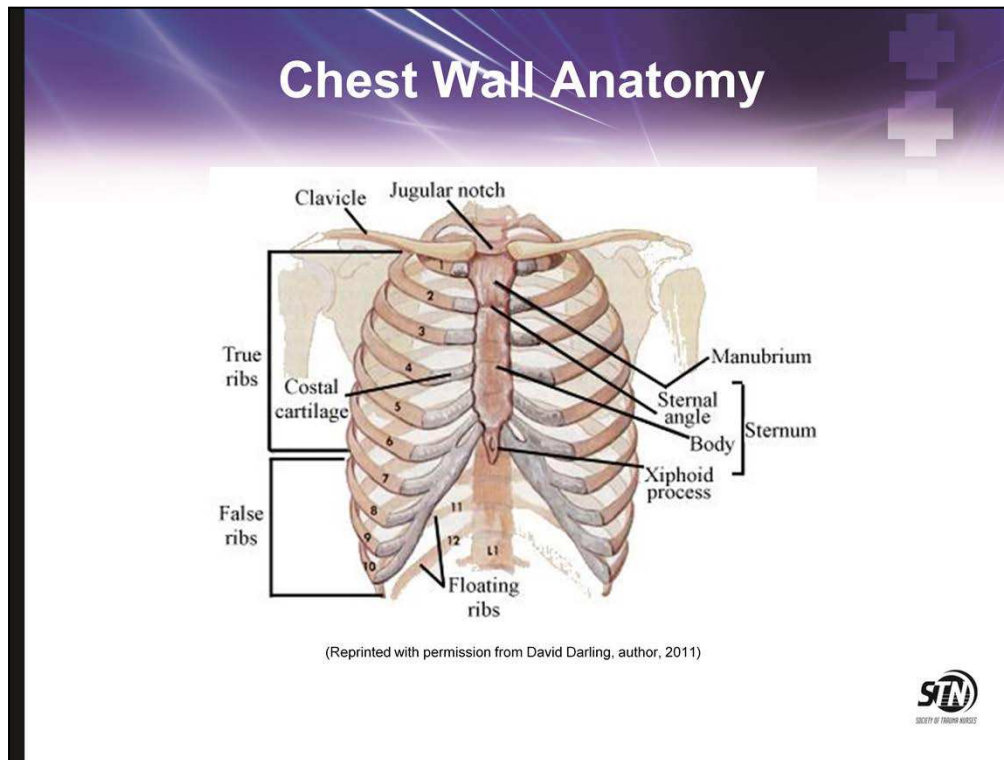
- Attention to airway, breathing, control bleeding, and treatment of shock is the focus of initial management of all trauma patients
- Attention to mechanism of injury important
- Life threatening injuries should be identified and treated during primary survey



In order to understand the propensity for injury, one must have an increased understanding of chest anatomy.

- The thorax is a large body cavity containing many vital structures.
- The thoracic wall is the outer protective shell comprised not only of the skeletal components of sternum, ribs, and spine but also of muscle layers and soft tissues.
- The thoracic cavity contain the lungs, tracheobronchial tree, heart, major vessels, esophagus, and diaphragm (which is also considered in the abdominal section due to its mobility during respiration)

Let's review each briefly.



First let's review the anatomy of the chest wall. Point out the structures.

Chest wall anatomy is comprised of bony and muscular structures which cover the chest cavity and protect the internal organs, mediastinal structures, and major vessels. Damage to the chest wall indicates damage to underlying structures and should be evaluated.

The lining of the chest wall is called the parietal pleura. The visceral pleura covers the organs.

Rib fractures


- Occur in about 66% patients involved in MVCs with chest trauma.
- Data that is available may actually underreport as many of these patients may be discharged from the ED.
- Fracture of the first, second ribs, clavicle and scapula should indicate a high index of suspicion for great vessel injury. It is associated with > 50% intrathoracic injury
- 12 pairs of ribs

- 1st 7 attached anteriorly via costal cartilages to sternum
- 8-10 connected anteriorly to each other via costal cartilages and synovial joints
- 11 & 12 ribs not connected anteriorly, floating ribs.
- Intercostal spaces: spaces between ribs; number to correlate with rib superior to space.
- Intercostal spaces contain muscles that are instrumental to work of breathing, arteries, veins, and nerves that run immediately under rib.
- Intercostal space named for rib above it.
- Landmark lines
 - ▶ 1st rib lies posterior to clavicles
 - ▶ Scapula ends at 7th intercostal space
 - ▶ Nipple on male at 4th intercostal space
- The bony structures also include the clavicle and scapula.


The Encyclopedia of Science

<http://www.daviddarling.info/encyclopedia/R/rib-cage.html>

Chest Wall Anatomy



- Scapula fractures**
 - Rare
 - Significant force
 - Increase suspicion for internal injuries
- Clavicle fractures**
 - Associated with:
 - 1st and 2nd rib fractures
 - Pneumothorax
 - Brachial plexus

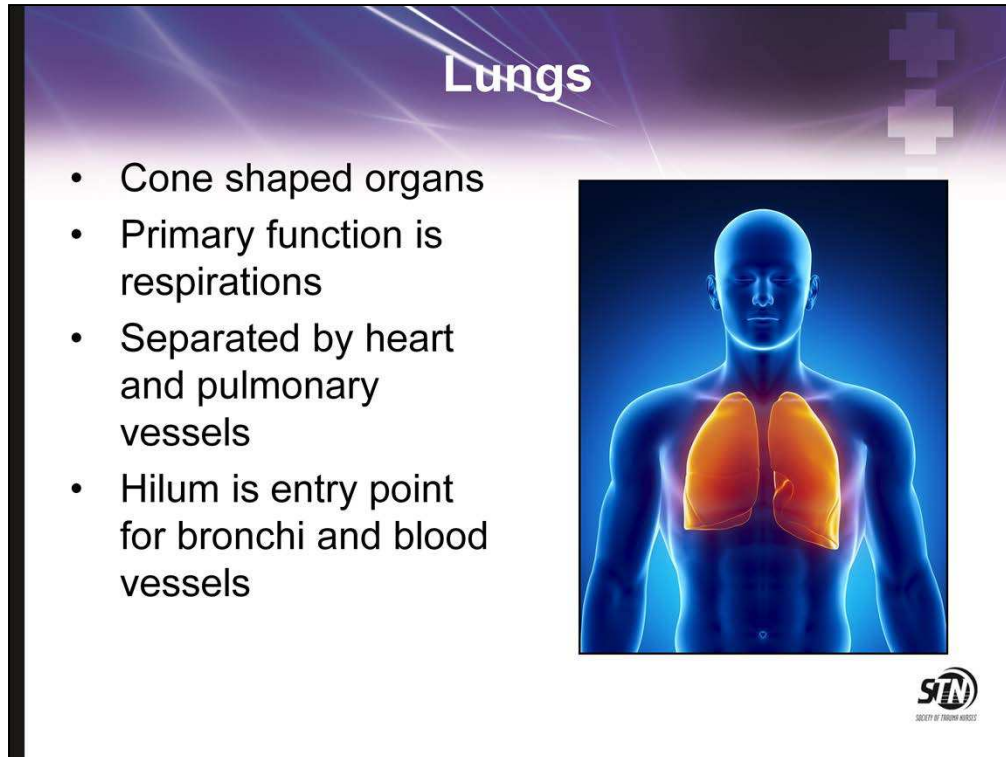


The clavicle and scapula are included as part of the bony thorax.

Point out the anatomy of the scapula.

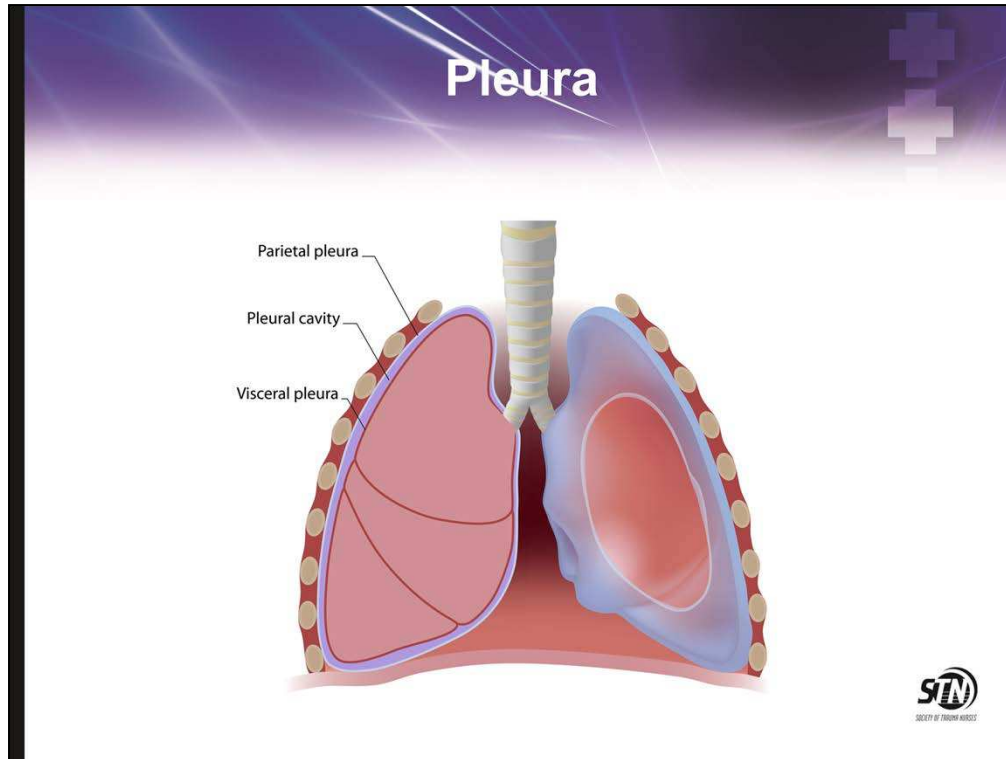
The scapula is encased in muscles and it takes tremendous force to cause a fracture.

Note the clavicles and potential or associated injuries.



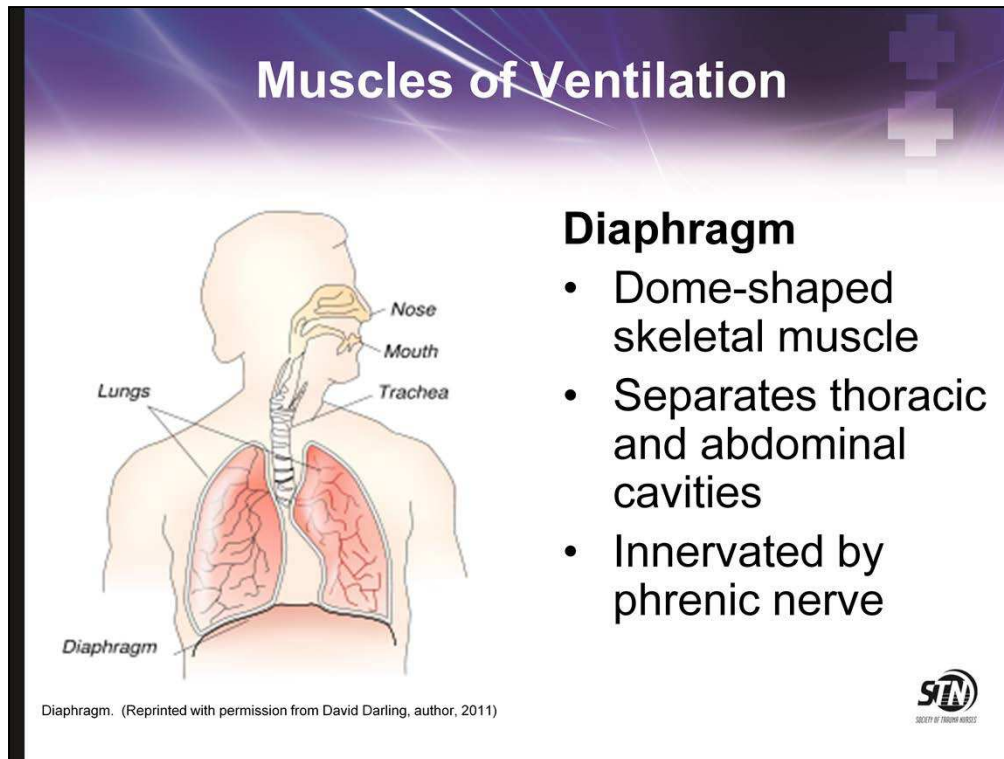
The lungs are located in two cavities on either side of the heart. Both are separated into lobes, with three lobes on the right and two on the left. The lobes are further divided into segments and then into lobules.

The right lung, although shorter and slightly broader than the left, actually has a total capacity and weight greater than the left lung. The diaphragm is higher on the right side to allow for the liver and its broadness also contributes to the heart leaning more to the left side.



Review the structure of the pleural cavity, parietal pleura, and visceral pleura.

Each lobe is surrounded by a pleural cavity consisting of two pleurae. The parietal pleura lies against the rib cage, and the visceral pleura lies on the surface of the lungs. In between the pleura is pleural fluid which helps to lubricate the lungs, as well as providing surface tension to keep the lung surface in contact with the rib cage.




- Inspiration: flattens to increase volume in thoracic cavity so air is drawn in
- Expiration: relaxes, restored to dome shape
- After the heart, most important muscle in the body

- Originates at T6 anteriorly and T10 posteriorly
- Phrenic nerve originates from cervical nerve roots 3-5
- "C3, 4, 5...keep diaphragm alive"
- Protected on right by liver, not as protected on left by stomach or bowel.

<http://www.daviddarling.info/encyclopedia/D/diaphragm.html> (location of diaphragm-
Image source:NIH)

Muscles of Ventilation

Intercostal Muscles	Accessory Muscles
<ul style="list-style-type: none">• External & Internal• Lift ribs to enlarge thorax• Innervated by intercostal nerves	<ul style="list-style-type: none">• Chest wall movement• Neck<ul style="list-style-type: none">• Sternocleidomastoids• Scalenes• Abdominal



- Pressure within lungs must be less than atmospheric pressure for inspiration to occur.
- Diaphragm and intercostal muscles work to increase size of thorax, intrathoracic pressure decreases below atmospheric pressure and air moves into lung
- Muscles relax during expiration and a rise in intrathoracic pressure causes air to move out of the lungs

Intercostal Muscles:

External: extend from ribs and vertebrae to origins of costal cartilage

Internal: extend from sternum to angles of ribs

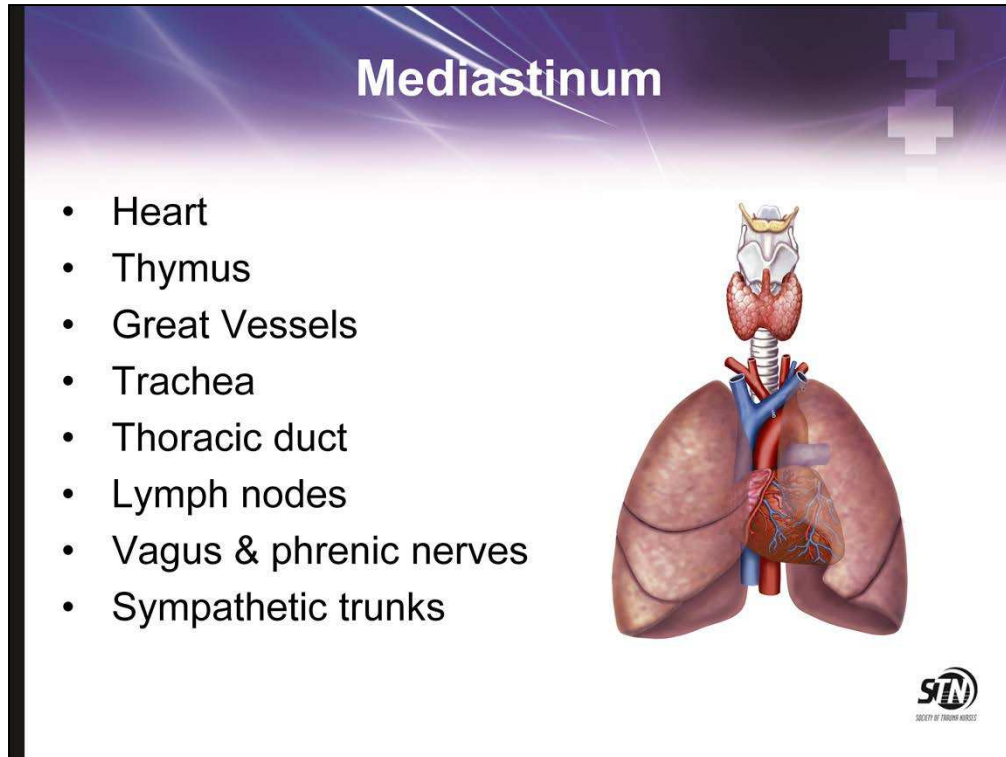
Thoracic spinal nerves branch out to form intercostal nerves

Accessory Muscles:

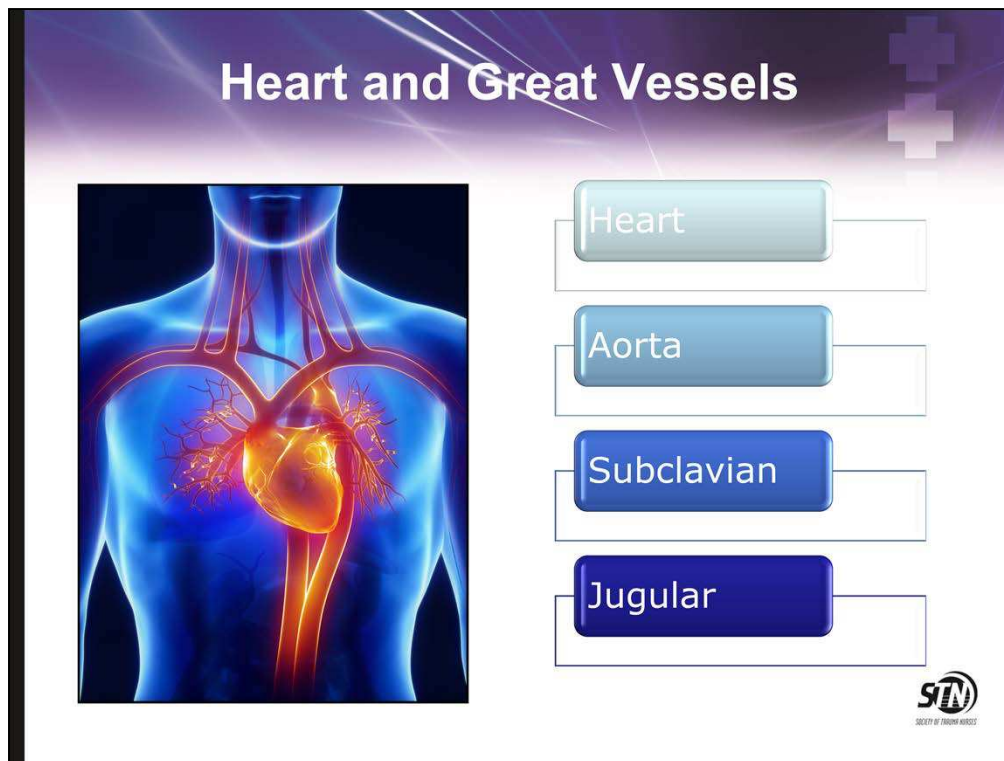
Neck: Sternocleidomastoids (raise sternum)

Scalenes (elevate 1st and 2nd ribs)

Abdominal: Augment rate and depth of breathing; generally implies an increase in work of breathing.

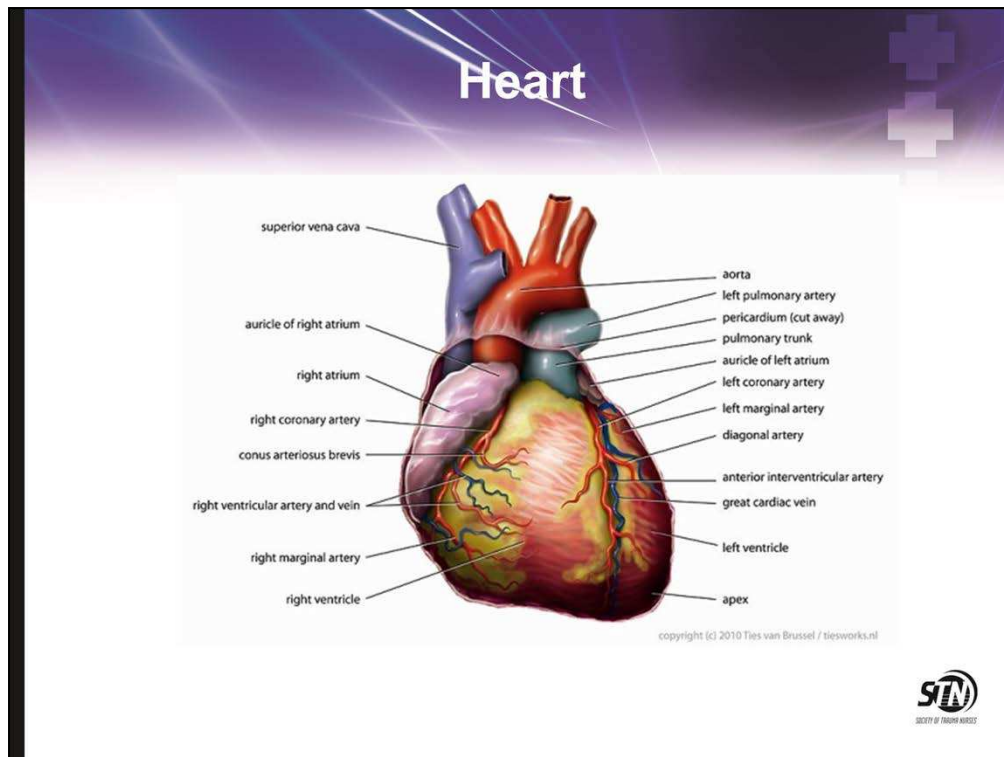


- The mediastinum is an anatomic division of the thorax extending from the diaphragm up to the thoracic inlet.
- It is the central portion of chest, lying between right and left lungs
- Note the structures listed and point out the anatomy.



Point out structures.

First, second rib fractures as well as scapula and clavicle fractures are associated with great vessel injury.



Heart

Obviously the most important muscle in the body.

A hollow muscle that pumps blood through the body by rhythmic contractions.

Enclosed in a double-walled sac called the pericardium.

Outer wall is comprised of three layers, the epicardium, the myocardium, and the endocardium.

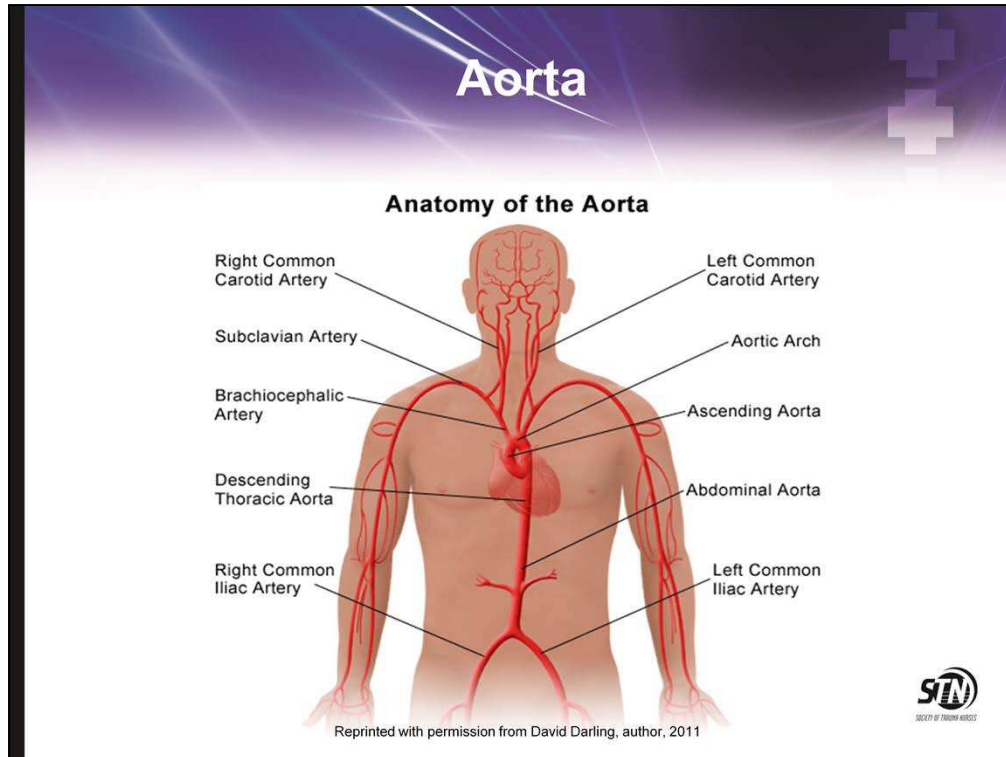
Has four chambers, two superior atria and two inferior ventricles.

The atria are the receiving chambers and the ventricles are the distributing chambers.

Describe the blood flow in review

- Deoxygenated blood flows through the heart in one direction
- Enters the right atrium through the superior vena cava
- It is then pumped into the right ventricle through the tricuspid valve
- Blood is pumped out through the pulmonary valve to the pulmonary arteries into the lungs where it is oxygenated
- It returns from the lungs through the pulmonary veins to the left atrium.
- It is then pumped through the mitral valve into the left ventricle
- It leaves this ventricle through the aortic valve to the aorta.¹

Photo with permission as part of public domain.



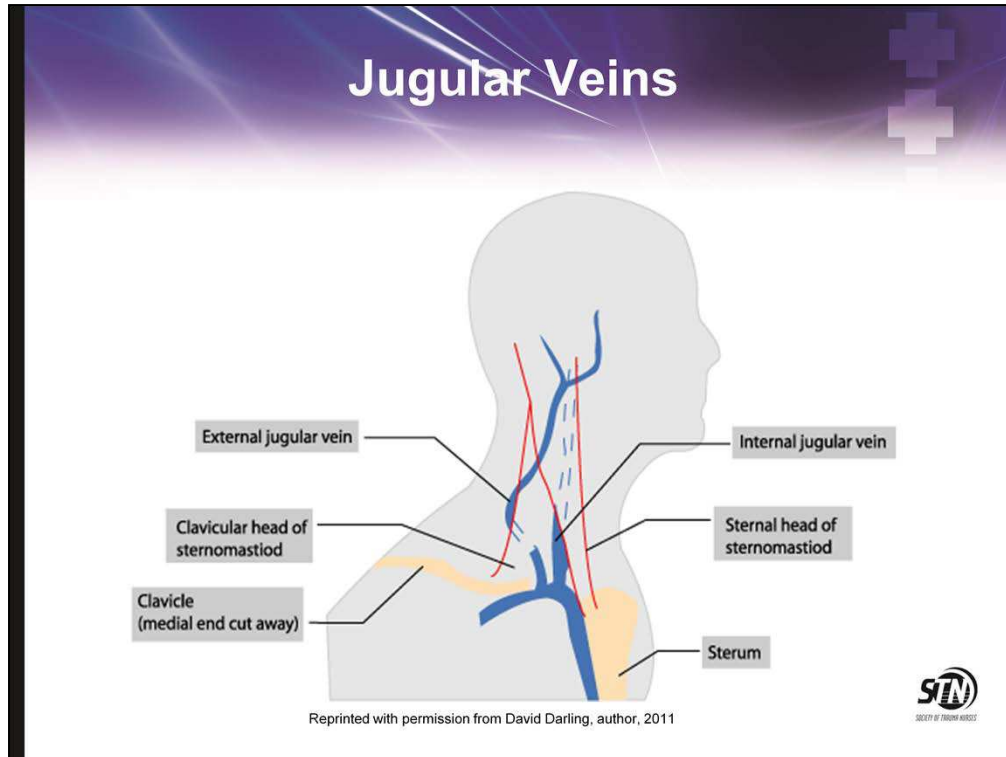
<http://www.daviddarling.info/encyclopedia/A/aorta.html>

Ascending aorta

Aortic arch

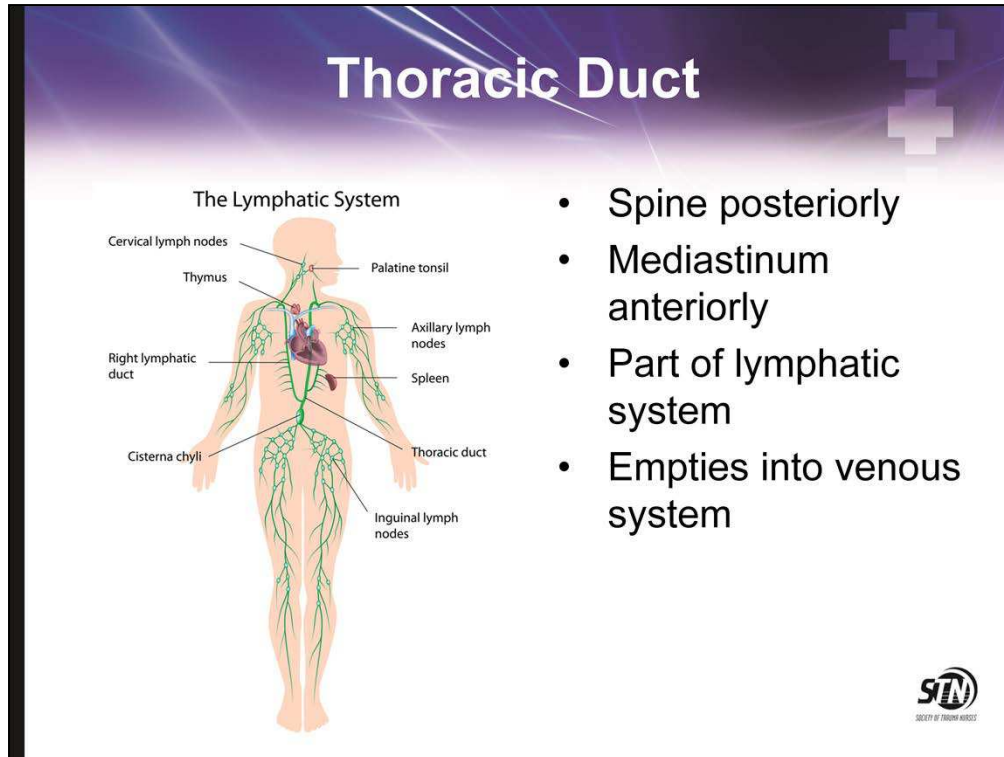
Descending aorta: runs down spinal column and subdivides into thoracic aorta, which descends within the chest and abdominal aorta, which descends within abdomen

Point out the subclavian vessels, tying the importance of bony structure injury overlying as a potential to injury, e.g. 1st, 2nd, and clavicle, scapular injuries.



- Jugular vessels
- External jugulars are above clavicles & cross over sternocleidomastoid muscles.
- Internal jugulars run parallel to sternocleidomastoid muscles near carotid arteries

http://www.daviddarling.info/encyclopedia/J/jugular_vein.html




Thoracic duct

- Protected posteriorly by spine and anteriorly by mediastinal contents
- Thin and fibromuscular and can be ruptured anywhere along its length
- Thoracic duct part of lymphatic system
- Enters thoracic cavity through aortic opening in diaphragm, crosses midline from right side of aorta at 5th thoracic vertebra, then ascends above left clavicle before arching back downward to empty into left internal jugular vein.
- Carries most of body's lymphatic draining
- Transports about 60% to 70% of ingested fat to blood stream
- Empties into venous system at junction of internal jugular and subclavian veins

Thoracic Assessment

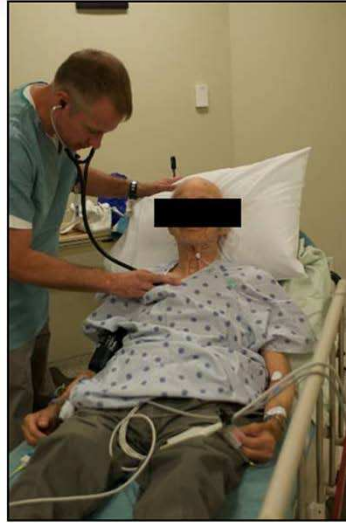- Obtain history of the event
 - Mechanism
 - Associated factors
- Perform a systematic assessment
 - Primary survey with ABCs
 - Secondary survey
 - Institute simultaneous interventions and diagnostic testing



- The information gathered from the prehospital setting is important. In general some important points to consider:
 - Motor vehicle collisions: speed, whether or not the patient was wearing a safety restraint, was their airbag deployment, their position in the car, area of impact and surrounding damage.
 - Motorcycle or bicyclist: if struck by vehicle and speed, if thrown and distance, etc
 - Pedestrians struck: the type vehicle and speed and if thrown and the distance.
 - Penetrating trauma: the type of firearm, caliber, distance; for stab wounds, the blade length and reported force.
- Keep in mind that in penetrating trauma, gunshot wounds have a less predictable pattern of injury as the missile may not follow a straight course. The effects of the “blast” may also cause injury. A common example is that of a pulmonary contusion.
- The physical examination should be an organized approach to include the primary survey with attention to any life threatening injuries followed by a secondary survey as taught in ATLS/ATCN courses.
- However, sometimes the exam is unreliable secondary to altered level of consciousness secondary to traumatic brain injury and/or alcohol and/or drug use, distracting injuries, or spinal cord injury and may signify the importance of further assessment in the absence of complaint.
- An EKG should be considered with anyone having significant chest trauma, and can be determined unnecessary after the H/P and clinical exam.

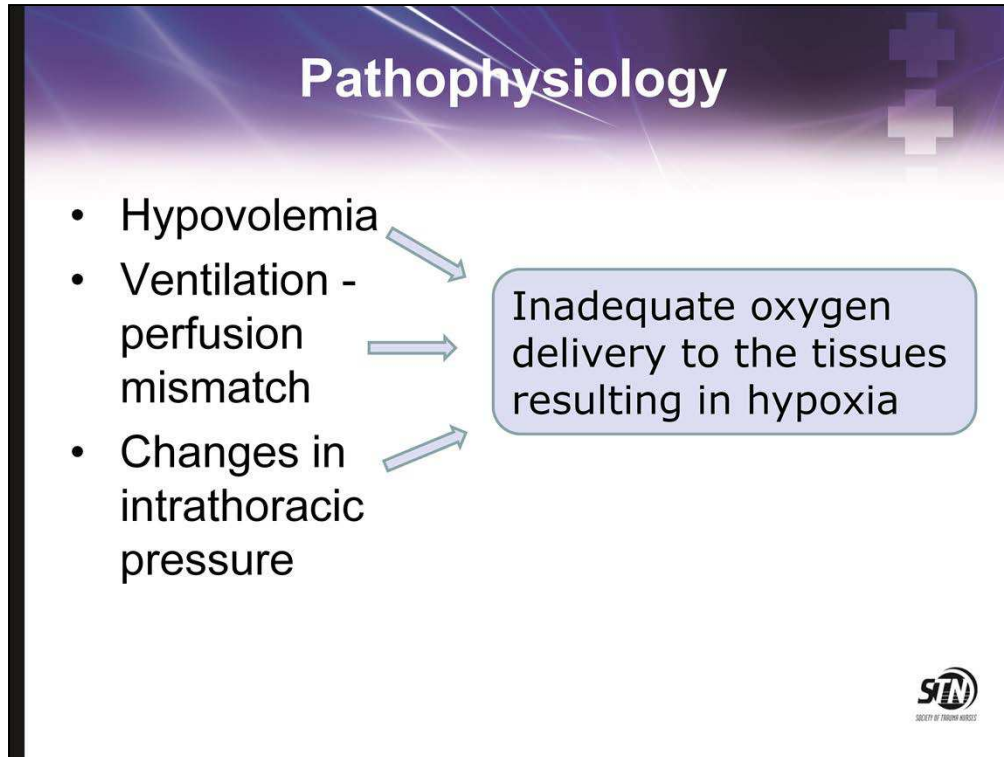
Common Findings

- Hypotension
- Hypoxia
- Tachycardia
- Shortness of breath
- Tachypnea
- Pleuritic chest pain
- Diminished breath sounds
- Subcutaneous emphysema



Findings will vary according to the injured structures or their affect on the body's physiology. There are some common findings in patient with chest trauma.

It is still important that one rely on physical exam.



Simplistic diagram for the most common physiologic issues in chest trauma

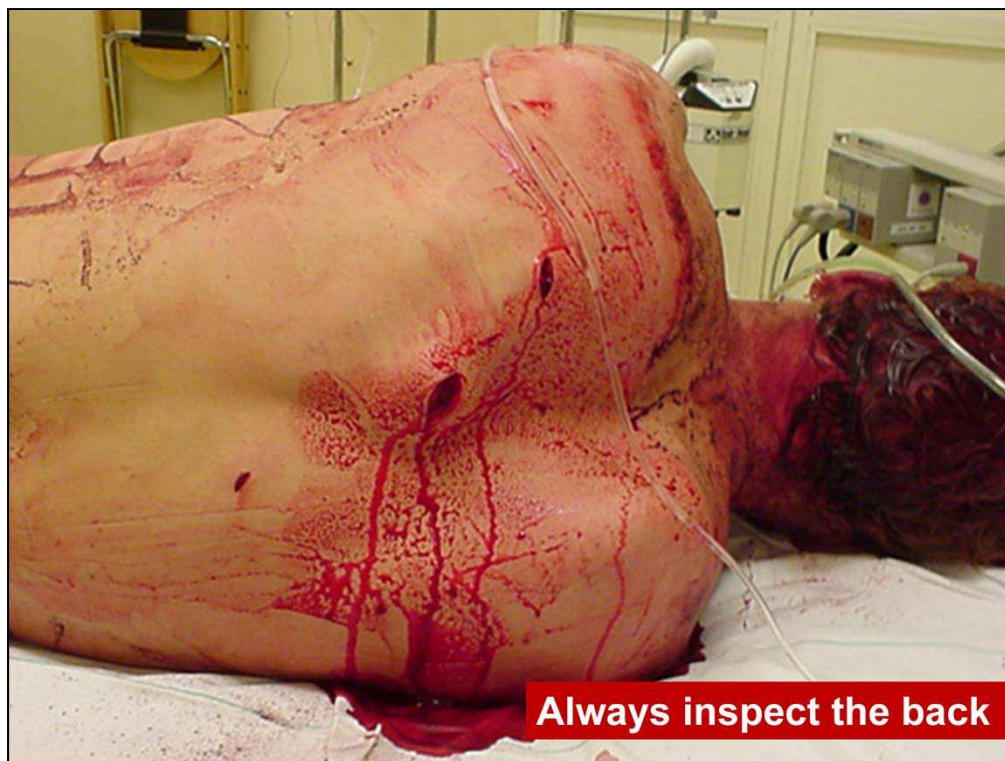Tissue hypoxia

Hypercarbia

Respiratory acidosis: inadequate ventilation

Metabolic acidosis: tissue hypoperfusion (e.g., shock)

Regardless of the injury, there are usually changes in the patient's ability to oxygenate and ventilate adequately.




Remember to always inspect the back.

Penetrating trauma may affect structures not apparent by outward wounds given the path the missile may take.

Diagnostic Radiology

Chest X-ray

- Early
- Valuable
- Significant injury
- Position of patient
- Never delay procedures for x-ray



- The CXR should be performed early; in ATLS , it is essentially an extension of the primary survey, simultaneously occurring during primary survey, or prior to the secondary survey.
- By doing early, the most life threatening injuries can usually be identified.
- If normal, the clinician can focus on other areas as the etiology of occult bleeding
- AP chest x-ray is perhaps the most valuable diagnostic study in the EARLY management of chest trauma
 - It is inexpensive, noninvasive and easy to obtain as a general rule.
 - It provides a quick assessment of significant bony, vascular, and lung related injuries.
 - In penetrating trauma, an upright film may be possible and provide answers to some of the early management priorities.
- Keep in mind that life-saving procedures should never be delayed in patients who has strong clinical suspicion based on history and exam.
- An example: 25 year old male presenting to the Trauma Bay following a MCC. The patient is in shock, BP 100/60, HR 140, RR 36. He is in respiratory distress with unilateral breath sounds. It should not take a CXR to confirm a hemopneumo or tension pneumo or for an astute clinician to know this patient requires an emergent chest tube.

Ultrasound

- Rapid
- Noninvasive
- No transport
- Evolving use
- Expertise in performing needed




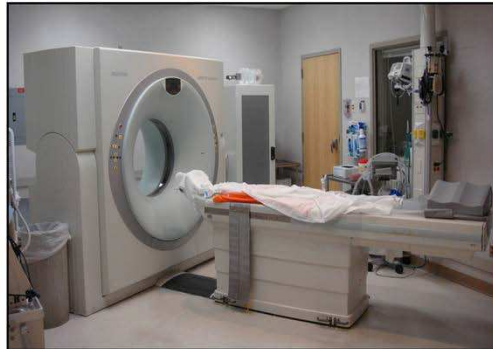Photo courtesy of Sonosite



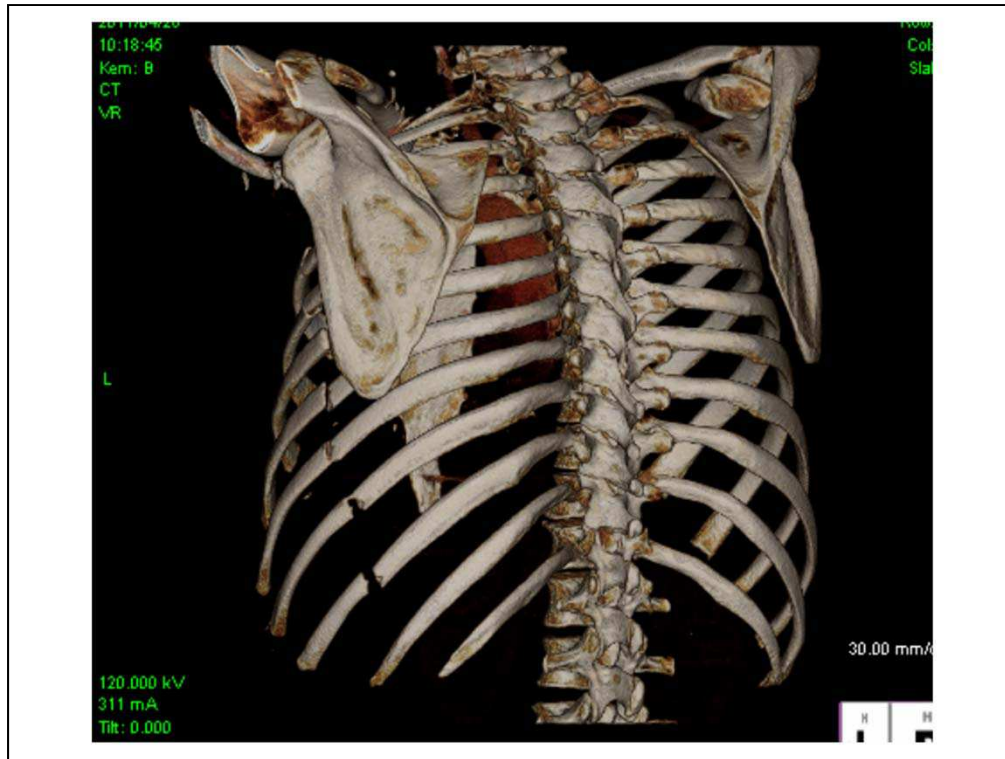
- Focused Assessment with Sonography in Trauma.
 - It is a rapid, portable, noninvasive, and accurate examination that can be performed to detect pericardial fluid collections.
 - Sonography is the gold standard for **rapid** diagnosis of traumatic pericardial fluid collections
 - Becoming increasingly more important in early management of thoracic trauma
 - Gaining popularity in the diagnosis of pneumothorax and hemothorax, however, its accuracy continues to be limited by the expertise of the operator.

Computed Tomography

- Used for hemodynamically stable patients
- Noninvasive procedure
- Newer helical scanners




- CT scan is the currently accepted standard of evaluation used in hemodynamically stable patients.
- CT scan more sensitive for pneumothoraces, fluid collections, and infiltrates, & aortic injury




Demonstrates details of rib fractures after 3-D reconstruction.

Arteriography



- Historically, gold standard
- New generation CT scanner images
- Lack of newer scanners
- Request of surgical subspecialists
- Stent placement




- Historically, biplanar digital subtraction angiography has been the gold standard for accurately diagnosing blunt and penetrating injury to the thoracic aorta and surrounding branches.
- As previously noted, new multidetector, helical CT scanners has evolved over the past decade to the point it can produce high resolution images that are comparable if not superior.




Let's now review some specific injuries and their evaluation and management.

For the purpose of this presentation, we have chosen to divide into life threatening injuries, potentially life threatening injuries and other common injuries.

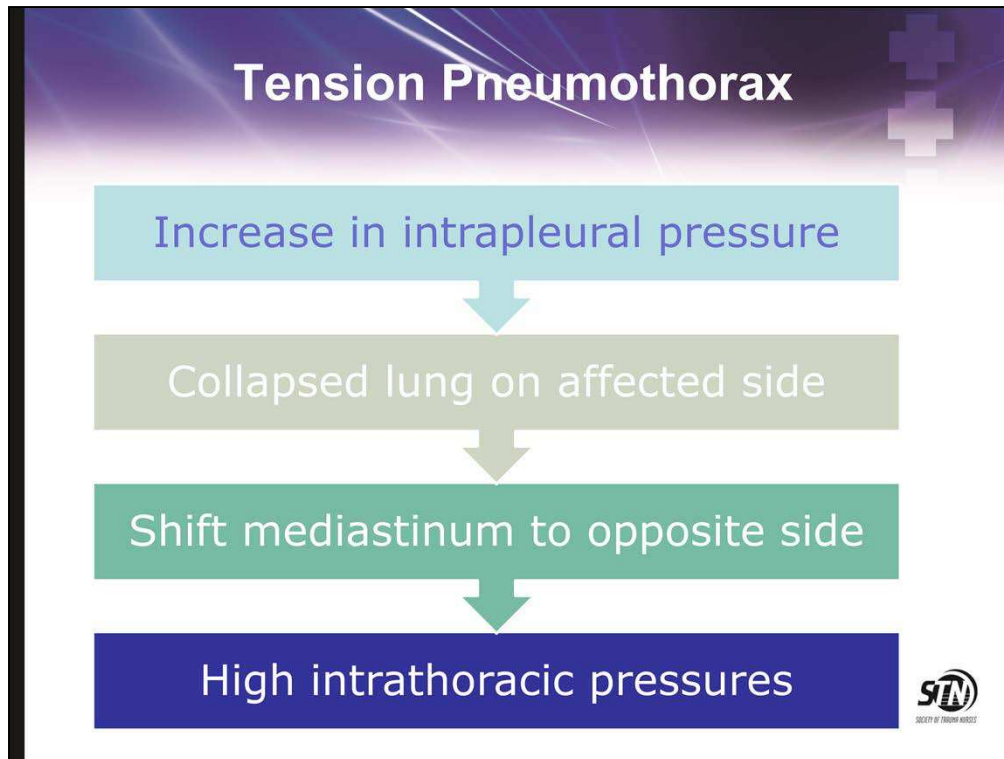
Immediately Life Threatening



- Airway obstruction
- Tension pneumothorax
- Open pneumothorax
- Massive hemothorax
- Flail chest
- Cardiac tamponade



These are life threatening injuries that should be recognized in the primary survey and intervened upon.



- Life threatening
- May result from primary trauma or secondary to treatment (barotrauma)
- Air accumulates within the pleural space on inspiration, but cannot escape on expiration, creating one-way valve
- Air accumulation causes an increase in intrapleural pressure (tension), collapsing lung on affected side, depresses diaphragm, & shifts mediastinal structures, (vena cava, trachea, heart) to opposite side.
- Mediastinal shift causes tracheal deviation within the thorax even though trachea felt midline on neck
- When intrathoracic pressures exceed CVP pressures, atria and vena cava compress, which creates blood flow obstruction to right heart.
- This causes a decrease in preload (venous return) and compromises cardiac output.

Risk for Tension Pneumothorax

- Extension from simple pneumothorax
- Tracheobronchial tree injuries
- Rib fractures
- Lung parenchyma injury
- Barotrauma
- Clogged/clamped chest tube




- Patients with tracheobronchial tree injuries, rib fractures, or damage to lung parenchyma are at high risk for developing a tension pneumothorax.
- Simple pneumothorax can lead to tension pneumothorax if not treated promptly
- Positive pressure ventilation may lead to barotrauma.
 - Patient will exhibit very high peak pressures
 - Unable to move air when bagging patient
- If you are bagging a patient with a pneumo/hemothorax during transport who is intubated, you should have a high level of suspicion for a tension developing.
- Non-patent chest tube can lead to tension pneumothorax.

Tension Pneumothorax

Symptoms

- Respiratory distress
- Absent/decreased breath sounds on affected side
- Asymmetric chest movement
- Jugular vein distention
- Tracheal deviation (late sign)
- Diagnosis should be made on clinical presentation

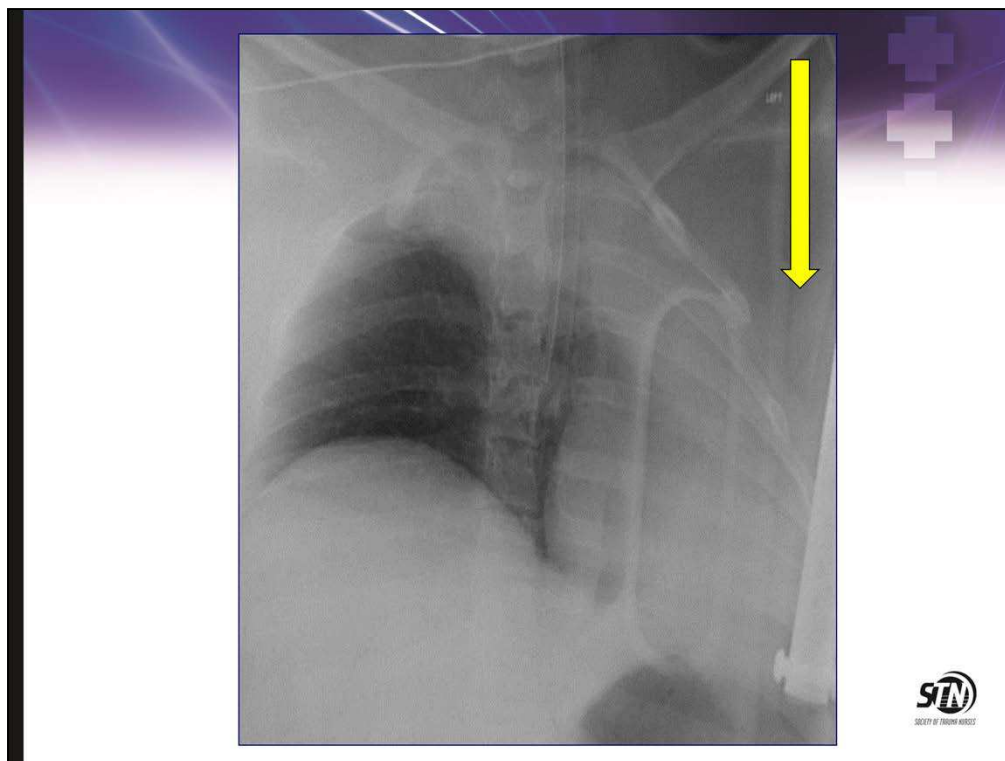


Inspect for chest pain, restlessness, severe agitation, dyspnea, and other signs of respiratory distress

JVD may be seen secondary to increased intrathoracic pressure, however, it is not a reliable finding and may be absent in hypovolemic patients.

Tracheal deviation in neck and cyanosis are late signs

Diagnosis should not be made by chest x-ray alone. A clinical exam should provide clues to patient's distress prior to radiographs being taken. A CXR confirms.



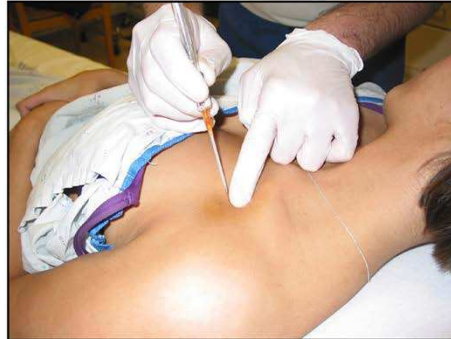Note the CXR where the heart and mediastinum is shifted toward the left side.

What side is the tension pneumothorax on? What side does the chest tube need to be placed? Right side

Tension Pneumothorax

Management

- Immediate decompression
- Large-caliber needle
- Second intercostal space, midclavicular line
- Chest tube (4-5th ICS)



Needle thoracocentesis

- Temporary intervention and is often done in the prehospital setting.
- 12-14 gauge catheter placed into 2nd-3rd intercostal space in midclavicular line
- Ensure catheter does not kink

Release of pressure will relieve symptoms, but will not re-expand lung.

Prepare for tube thoracostomy (chest tube insertion) at 4th-5th ICS, midaxillary line

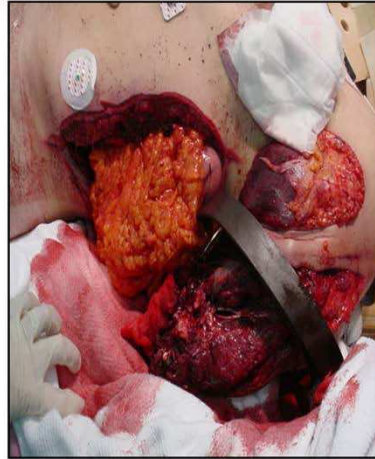Note needle placement in image. Also note that a 14 g (insyte brand) catheter over needle is being used.

NOTE: If a patient does not improve and remains in respiratory distress evidenced by increased respiratory rate and hypoxemia, and a continuous air leak, consideration should be given to an injury to the tracheobronchial tree.

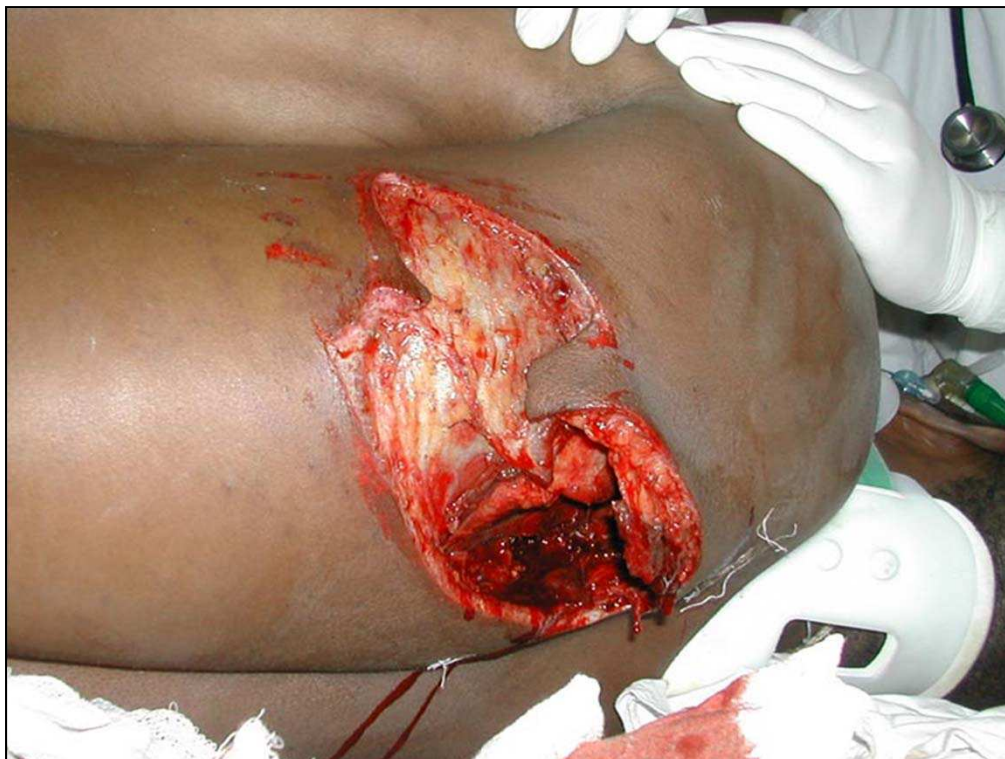Open Pneumothorax

“Sucking Chest Wound”

- Visible chest wound bubbling with frothy blood
- Sucking sound near wound
- Subcutaneous air
- Respiratory distress



- Seen as a result of penetrating trauma such as a shotgun blast, impalement injuries or boat propellers as in the photo above.
- Known as a “sucking chest wound” by its characteristic sound due to open communication between environment and pleural space
- Hypoventilation and hypoxia result and respiratory distress may progress rapidly and even result in death if the wound in the chest wall is not covered to prevent further passage of air in/out of the chest



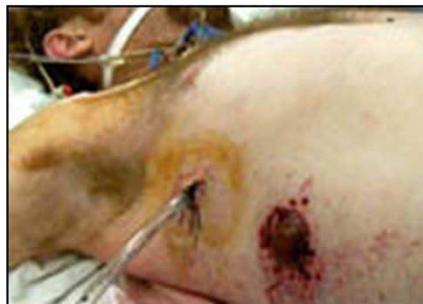- Normal ventilation requires negative intra-thoracic pressure
- Large open chest-wall defect → causes equilibration of intra-thoracic and atmospheric pressures
- If hole greater than two thirds tracheal diameter, air enters chest defect

Another example of an open wound to the posterior thorax resulting in open pneumothorax.

Open Pneumothorax

Treatment

- Intubation if in respiratory distress
- Cover with sterile, occlusive dressing
- Three-sided dressing to create flutter valve
- Chest tube placement
- Plan for thoracotomy



In the field:

- Medics are taught to initially place a nonporous dressing. This somewhat restores chest wall integrity to improve ventilatory efforts.
- One side of dressing must be left untaped to allow air to exit and avoid tension developing

In the hospital setting:

- Once chest tube is inserted, apply an occlusive dressing over open pneumothorax site.
- Continue to monitor for tension pneumothorax due to an ongoing internal air leak
- Note the patient's open wound and the right chest tube.

Massive Hemothorax

- Class III or IV hemorrhage
- Chest tube insertion
- Autotransfusion
- Blood transfusion
- Thoracotomy indications
 - Hemodynamically unstable
 - Initial output of ≥ 1500 ml of blood from the pleural space
 - Ongoing bleeding > 200 ml per hour for ≥ 4 h



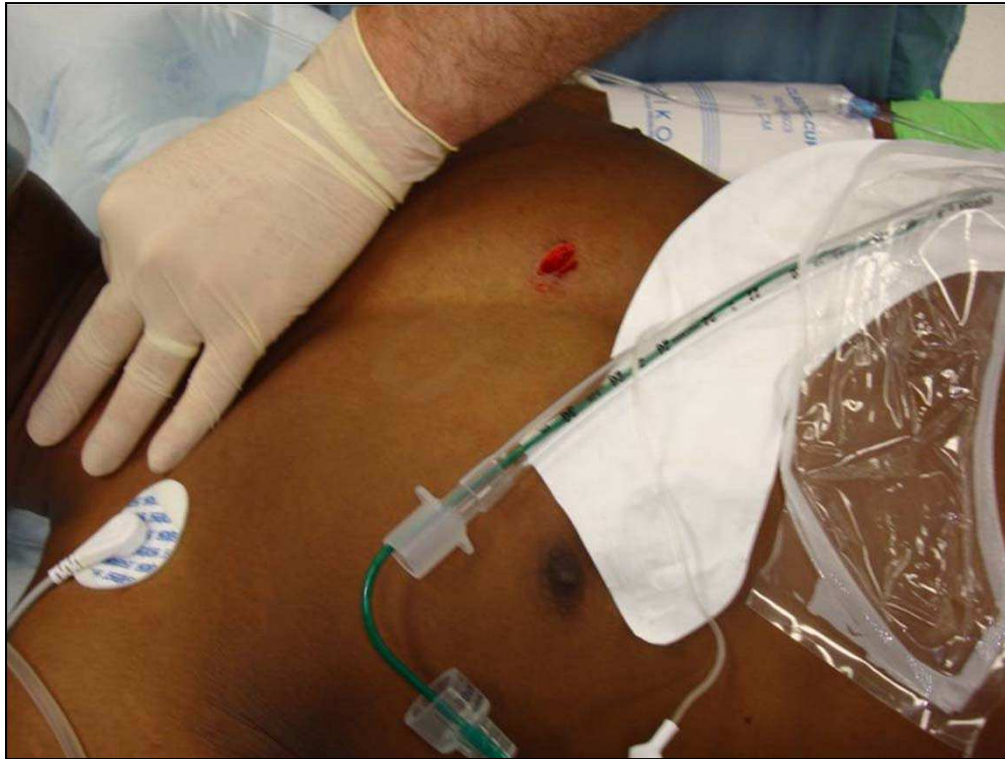- Accumulation of ≥ 1500 mL in the pleural space and associated with signs of shock and hypoperfusion
- Each hemithorax can hold up to 3 liters of blood
- Class III or IV hemorrhage
- Presents in shock and respiratory distress
- Prepare for 36-40 F chest tube to allow easy drainage and to prevent clotting
- Monitor chest tube output
- Autotransfusion:
 - Considering the costs and risks of blood transfusion, autotransfusion is recommended for moderate to large hemothoraces whenever possible

Autotransfusion blood from chest tubes reduces coagulopathy and inflammatory response to the injury

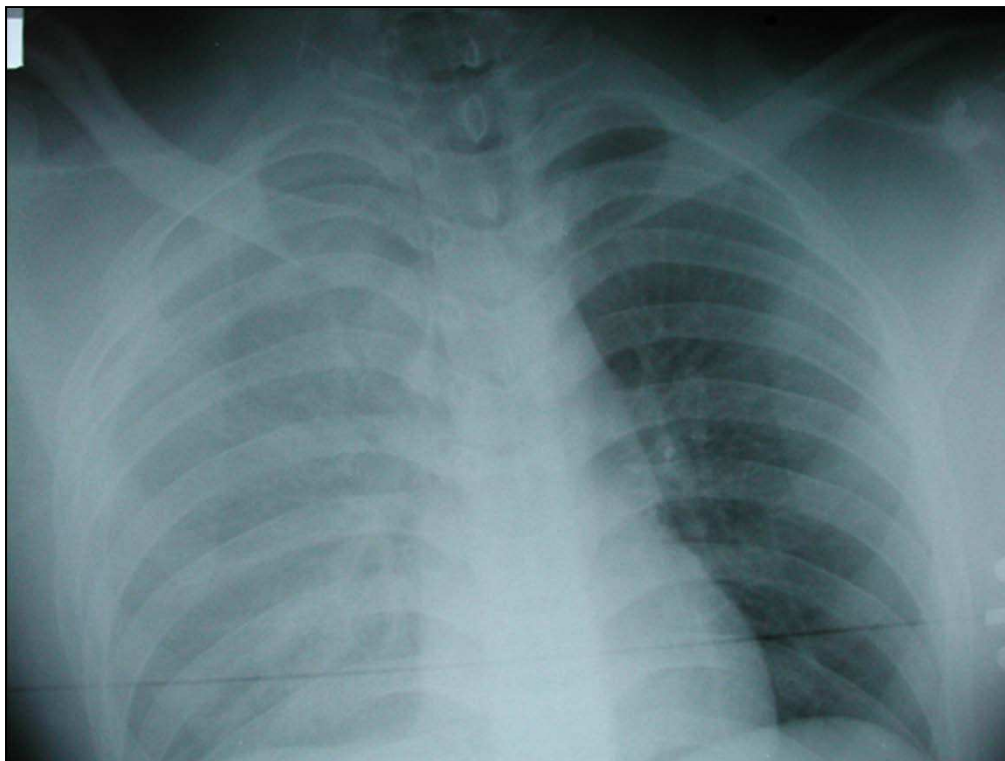
► Autotransfusion blood from chest tubes reduces coagulopathy and inflammatory response to the injury

- Is autotransfusion performed in your center?
- What equipment do you use?
- Do you add an anticoagulant?
- Does it begin in the ED or is the patient in the OR?
- Is cell saver used?

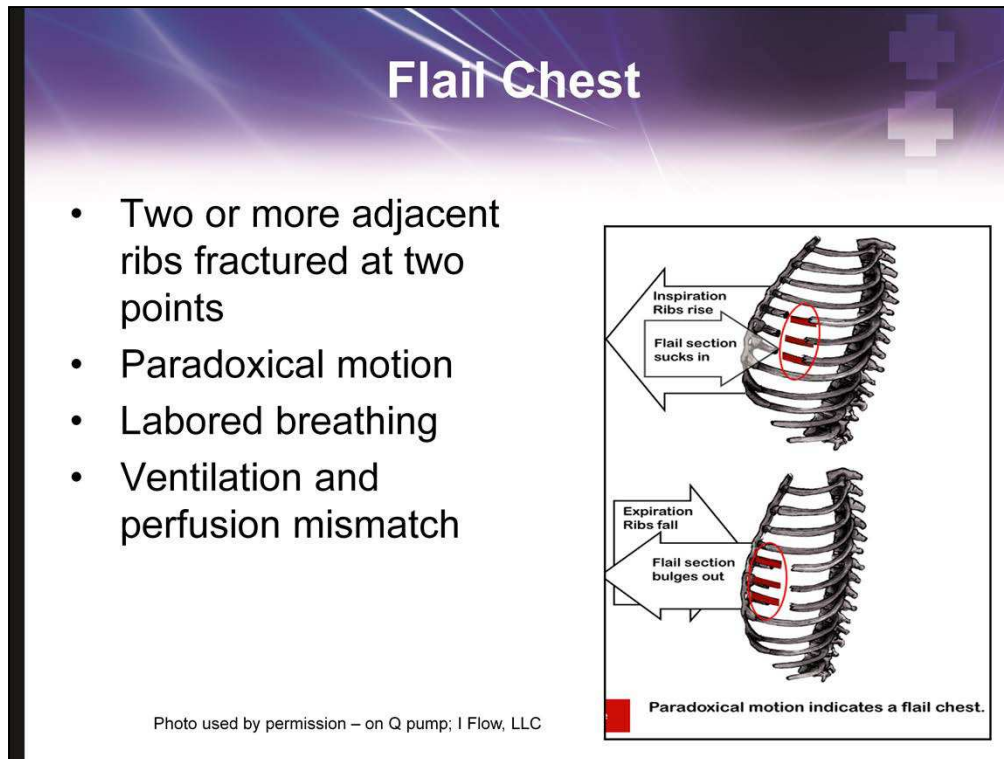
Trauma, pg 538-540



Note the stab wound to the left chest.

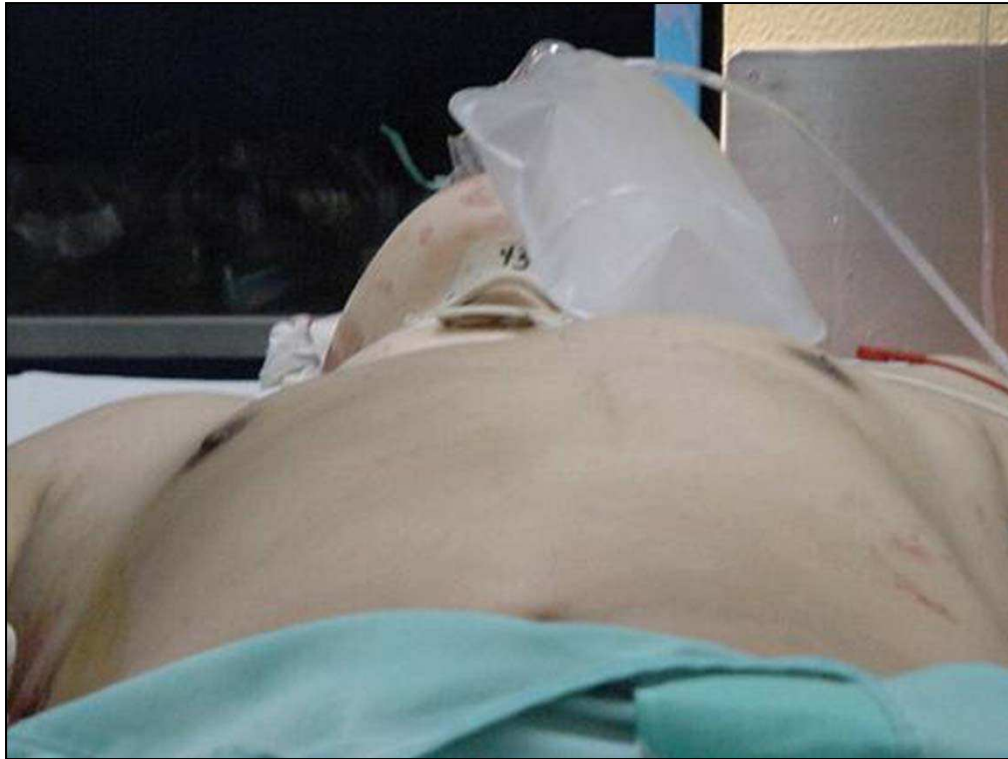

Note the right chest which is full of blood. Massive right hemothorax.



Review the paradoxical motion of a flail chest.



- There are differences in the literature of what constitutes a flail chest as well as what is a flail chest vs a flail segment. References utilized in this presentation noted either two or three ribs fractured in two places creating an unstable segment.
- Paradoxical movement may not be initially apparent in awake patient with muscle spasms, shallow respirations, and splinting secondary to pain or in a patient who is on positive pressure ventilation
- Usually see within first 24 hours if not initially as patient tires.
- Hypoxemia may require intubation



Notice the asymmetrical chest wall.

Flail Chest


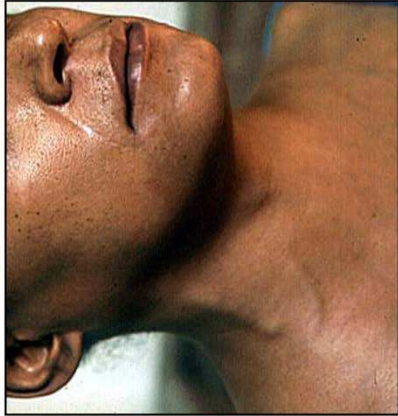
- Associated with pulmonary contusion
- Pain
- Hypoventilation
- Potential injury to underlying organs



- Most flail chest managed non-operatively, but operative management is making a recurrence given advances in instrumentation
 - Some are of the opinion that operative chest wall stabilization will not benefit most of patients with flail chest and significant pulmonary contusion
 - If undergoing thoracotomy for other indications, fixation of ribs using wires or small plates will provide improved chest wall stability and should be done at time of closure
 - There is some literature that disputes this perspective and experts experience documents improvements in patient's pain, decrease vent days, and decreased LOS
 - Sternal Flail Chest: separation of sternum from adjacent broken ribs or costochondral joints
 - Associated abdominal injuries occur in about 15%.
-
- Ensure oxygenation
 - Provide analgesia
 - Pulmonary toilet

Pericardial Tamponade

- Anxious
- Reluctant to lie flat
- Feeling of “impending doom”
- May have “Beck’s triad”
 - Distended neck veins
 - Hypotension
 - Muffled heart sounds
- + FAST



Usually from penetrating injuries but can be seen in blunt trauma victims.

“Beck’s triad” present in only about 33% patients

- Distended neck veins from elevated venous pressure (note the photo)
- Decreased arterial BP
- Muffled heart sounds

Patient will remain hypotensive despite adequate blood and fluid resuscitation.

FAST for evaluation of blood in pericardial sac

Blood in pericardial sac prevents contractility of the heart.

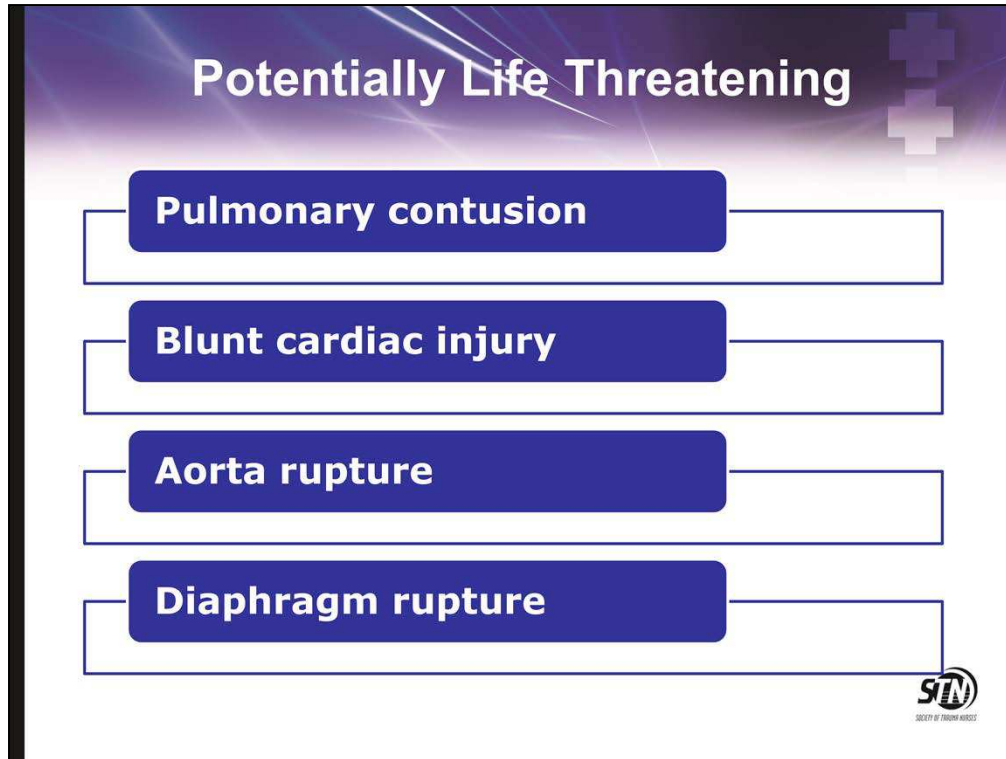
PEA may result since there is no pump action to create a pulse but an electrical rhythm remains on the monitor.

Pericardial Tamponade

- Pericardial sac is nondistensible
- Excess fluid decreases ventricular filling & stroke volume
- Pericardiocentesis
 - Temporizing measure
 - 16- to 18-gauge needle
 - Repeat as needed to keep SBP > 90 mm Hg
- Pericardial window



- Pericardial sac normally contains 20-30 ml of serous fluid and will not distend so a small amount (75-100 ml) may actually compress the heart and restrict its ability to contract.
- Normal compensatory mechanism is increase in heart rate which initially sustains BP, but decreases peripheral perfusion
- Fall of systolic blood pressure is result of excessive right ventricle filling which then causes interventricular septum to shift to the left
- This septal shift impairs left ventricular filling causing fall in cardiac output
- Increasing pericardial pressure decreases coronary blood flow resulting in myocardial ischemia and cardiac decompensation
- Inadequate peripheral perfusion intensifies metabolic acidosis, which also weakens myocardial contractility
- Distended superficial neck veins is late sign and is more prominent during inspiration (Kussmaul's sign)
- Pericardiocentesis
 - Currently, is minimally used in Level I trauma center
 - Can be done as a temporizing measure until pericardiotomy can be performed
 - Place patient supine position with head and torso elevated 45 degrees
 - 16- or 18-gauge needle attached to 60-ml syringe
 - Insert needle left side of xiphoid, pointing toward posterior aspect of left shoulder
 - Popping sensation usually felt when pericardium entered
 - Withdrawal of small amount can be life saving
 - Repeat as frequently as needed to maintain SBP > 90 mm Hg
 - Can inadvertently cause iatrogenic injury to coronary artery, myocardium, etc.
- Pericardial window is preferred in hemodynamically stable patients. Procedure can be done in the OR under more controlled circumstances and the ability to further intervene with additional procedures is readily available.



These injuries will now be briefly reviewed. They are somewhat more difficult or delayed in their presentation/diagnosis, however, if not found can be lethal.

Pulmonary Contusion

- Occurs in 30-75% of all blunt thoracic trauma
- Develops over time
- Bruising of lung tissue
- Diffuse hemorrhage with interstitial and alveolar edema
- Impairment of gas exchange



Most common mechanism is MVC.

It is the most common, potentially lethal chest injury.

Usually associated with flail chest or rib fractures. In children, it may be isolated without rib fractures due to the resiliency of the chest wall.

It can also be associated with penetrating trauma due to the blast effect.

More interstitial and intra-alveolar fluid increases which causes impaired gas exchange.

Animal studies demonstrate

Local: Lung tissue laceration

Hemorrhage-filled alveoli

Reduced compliance leading to reduced ventilation

Increased shunt fraction with decrease in oxygen and increase in alveolar-arterial oxygen difference)

Increased pulmonary vascular resistance

Decreased pulmonary blood flow

Thickened alveolar septa with impaired diffusion

Delayed capillary leak with increased BAL (bronchoalveolar lavage) protein

Increased neutrophils in lung tissue

EAST Practice Management Workgroup for Pulmonary Contusion-Flail Chest. (June 2006). Practice Management Guideline for Pulmonary Contusions-Flail Chest. Eastern Association for the Surgery of Trauma. Available on-line: www.east.org/tpg/pulmcontflailchest.pdf.

Assessment and Treatment

- Hypoxemia and respiratory compromise
- Bloody sputum, secretions
- Chest x-ray: patchy infiltrates or consolidation hours after injury
- Oxygen therapy and aggressive pulmonary toilet
- Ventilator strategies

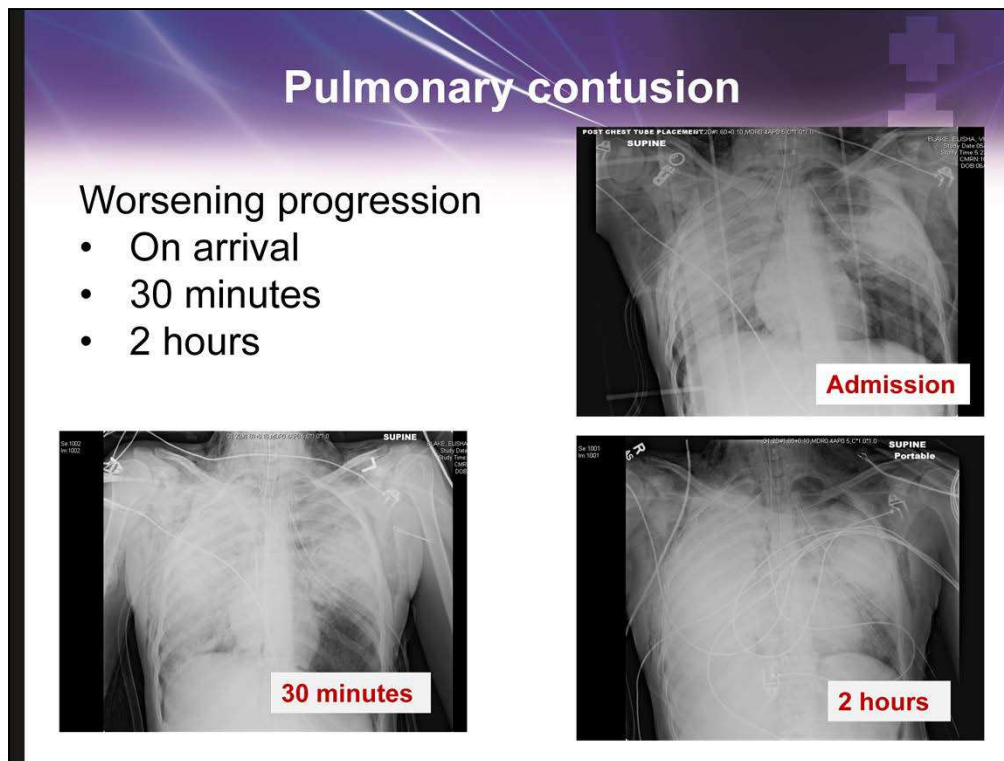


Aggressive treatment is important to avoid complications.

If mild, a patient can be treated with oxygen, saturation monitoring, pulmonary toilet and analgesia.

If it is more moderate to severe, the patient may require intubation with PEEP.

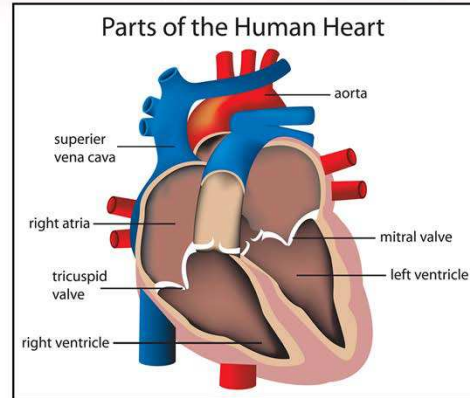
When patient is not responsive to conventional ventilation, other modes may be beneficial, e.g. pressure control, APRV, PRVC, jet ventilation, etc. There are some facilities that have ECMO capabilities and the benefits of this treatment in adults is still evolving.



Progression of pulmonary contusions, initial, 30 minutes after arrival, 2 hours post arrival

Blunt Cardiac Injury

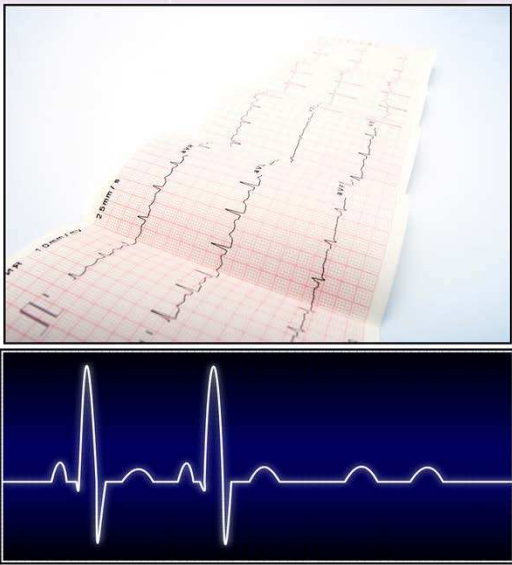
- Mild tenderness to chamber rupture
- Types of injuries
 - Compression
 - Deceleration
 - Blast
 - Direct impact



- Blunt cardiac injury can range from mild myocardial contusion to frank cardiac chamber rupture
- Result secondary from compression, deceleration, blast or direct forces to the chest
- Critical injury resulting in hemodynamic instability is rare.

Assessment

- Chest pain
- Arrhythmias
- Electrocardiogram
- Echo
- Lab panel



Patients may or may not complain of chest pain.

- Presentation may include tenderness and pain over chest wall to signs of pericardial tamponade
- EKG used as screening tool. If normal in hemodynamically stable patient warrants no further investigations
- Echo can be used to assess wall function and valvular competency

A 12-lead electrocardiogram

The 12-lead electrocardiogram (ECG) is a standard test that can help identify new cardiac abnormalities and help discover underlying problems that may impact treatment decisions. It is especially helpful in the older population or those with premorbid conditions. The most common ECG abnormalities found in patients with blunt cardiac injuries are tachyarrhythmias and conduction disturbances, such as first-degree heart block and bundle-branch blocks.

Serum troponin levels

Troponin is a protein specific to cardiac cells and elevations correlate with Echo or EKG abnormalities in patients with cardiac injuries but have a low sensitivity and predictive value in diagnosing BCI or myocardial contusion. By itself, it does not help predict the occurrence and their routine use in this clinical situation is not well supported.

Serum myocardial muscle creatine kinase isoenzyme levels

Measurement of creatine kinase-MB levels is frequently performed in patients with possible blunt myocardial injuries. This diagnostic modality has poor sensitivity, specificity, and positive predictive value in relation to clinically significant blunt myocardial injuries.

Traumatic Aortic Disruption

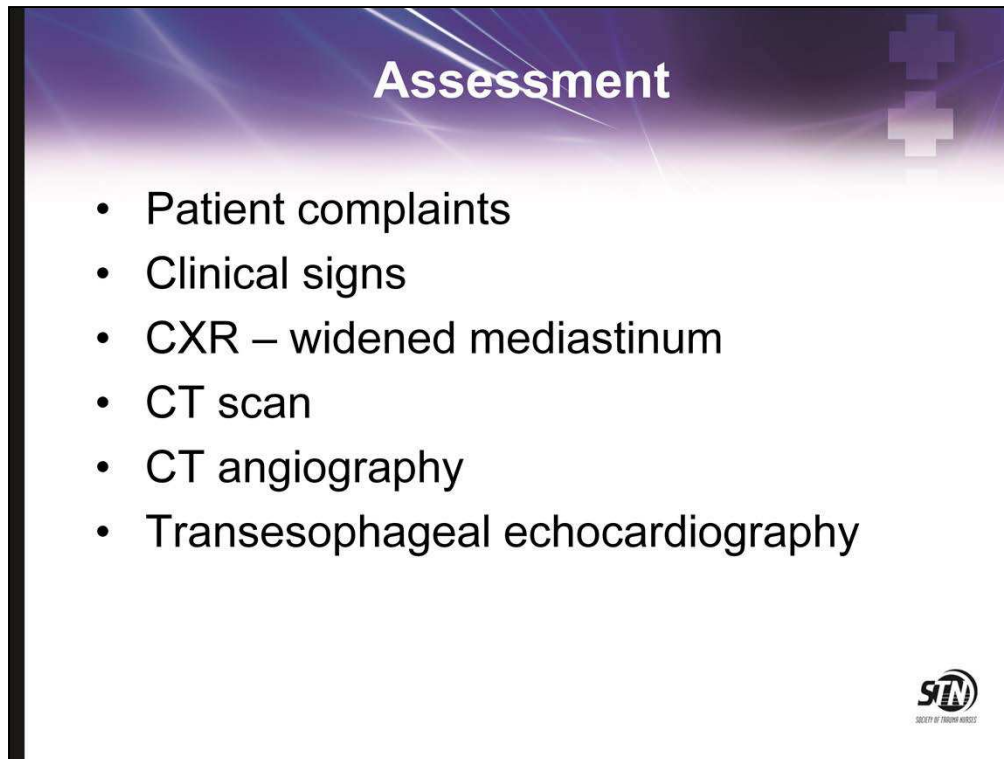
- Common cause of death at scene
- Survivors may have incomplete laceration or hematoma
- Most common site is distal to left subclavian artery
- Not always with specific symptoms
- Maintain high index of suspicion for deceleration type of injuries



- Common cause of sudden death following MVC or fall from height...deceleration injuries.
- More survivors now than historically in some areas of the country due to improved trauma systems, EMS transport, access to care, etc
- Survival depends on incomplete laceration near ligamentum arteriosum or hematoma at site
- Must have high index of suspicion
- May not have specific symptoms
- Delay in recognition may result in early in-hospital rupture

ATLS pg 95

Associated injuries in patients with blunt aortic injuries are found in 81%.
Injuries in drivers may differ from those in passengers.

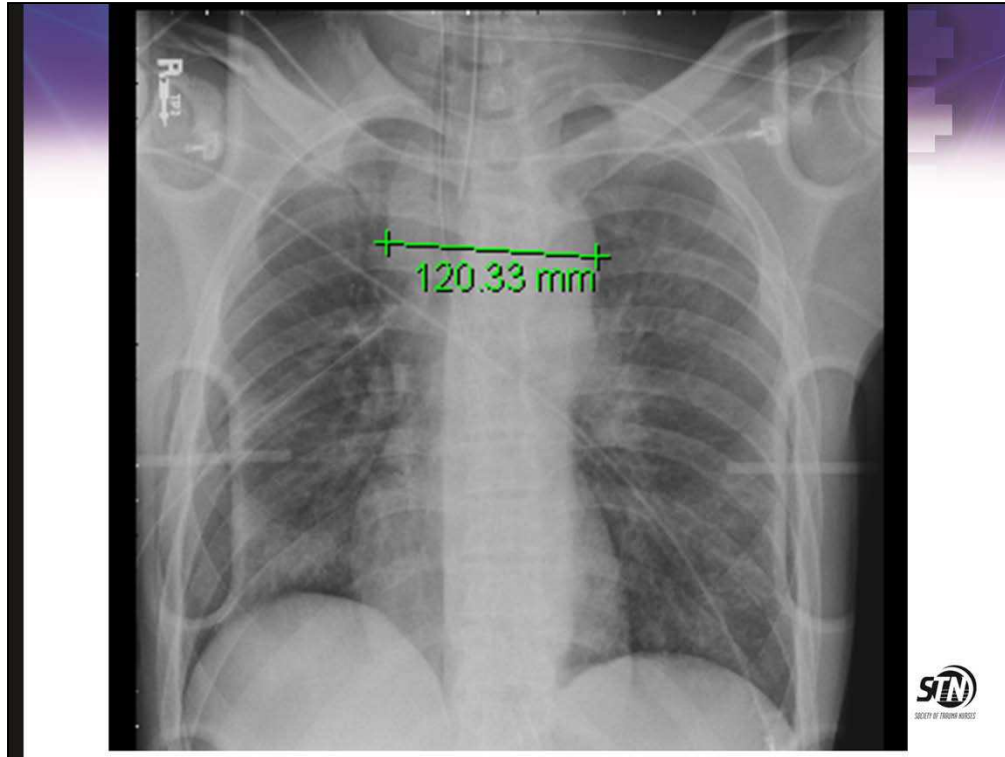


Some patients do not complain of pain while others may have general complaints, nonspecific to aortic injury, such as difficulty breathing, while others should raise suspicion such as intrascapular pain.

Clinical signs may include new onset murmur, upper extremity hypertension or bilateral femoral pulse deficit

CT angio is an appropriate test over formal arteriography in the diagnosis. In fact, with the new helical scanner and improved imaging, it has been shown to be highly sensitive and specific, approaching that of arteriography and one reference citing a study indicating higher.

TEE – may be useful in hemodynamically unstable patients as it can be performed in the ED, the OR, however, does require the expertise of someone trained to use and their availability e.g. cardiologist, anesthesiologist, etc.




X-ray of widened mediastinum. Transected aorta.

Diagnostics

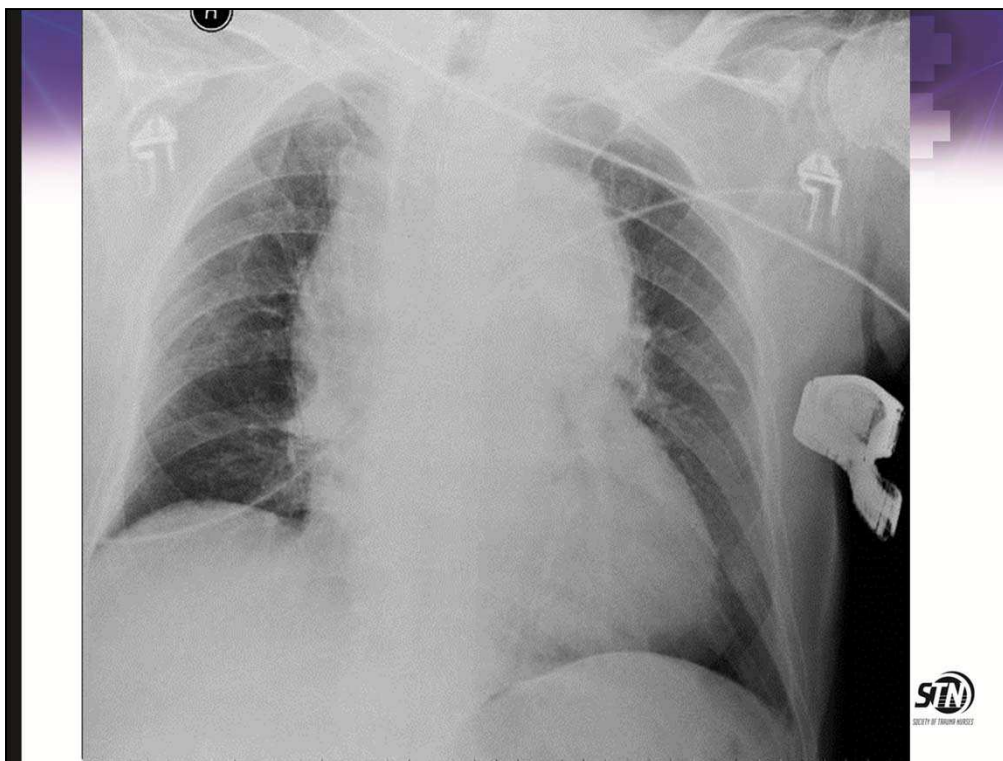
CXR

- Wide mediastinum
- Obscured aortic knob; aortic contour
- Left apical cap
- Large left hemothorax
- Deviation of the gastric tube to the right
- Deviation of the trachea to the right or right mainstem bronchus down
- Wide left paravertebral stripe



Keep in mind a widened mediastinum is somewhat common but sensitive sign of aortic injury. Only an estimated 20% have this finding.

On supine films, consider > 8 cm concerning; upright films, > 6cm.



Widened mediastinum – ruptured aorta

CT Angiography/Arteriography

- Confirms injury location
- Helps surgeon formulate an operative plan
- Detects active bleeding in patients with vascular trauma
- Emblazes specific structures as indicated
- Stenting for certain aortic injuries

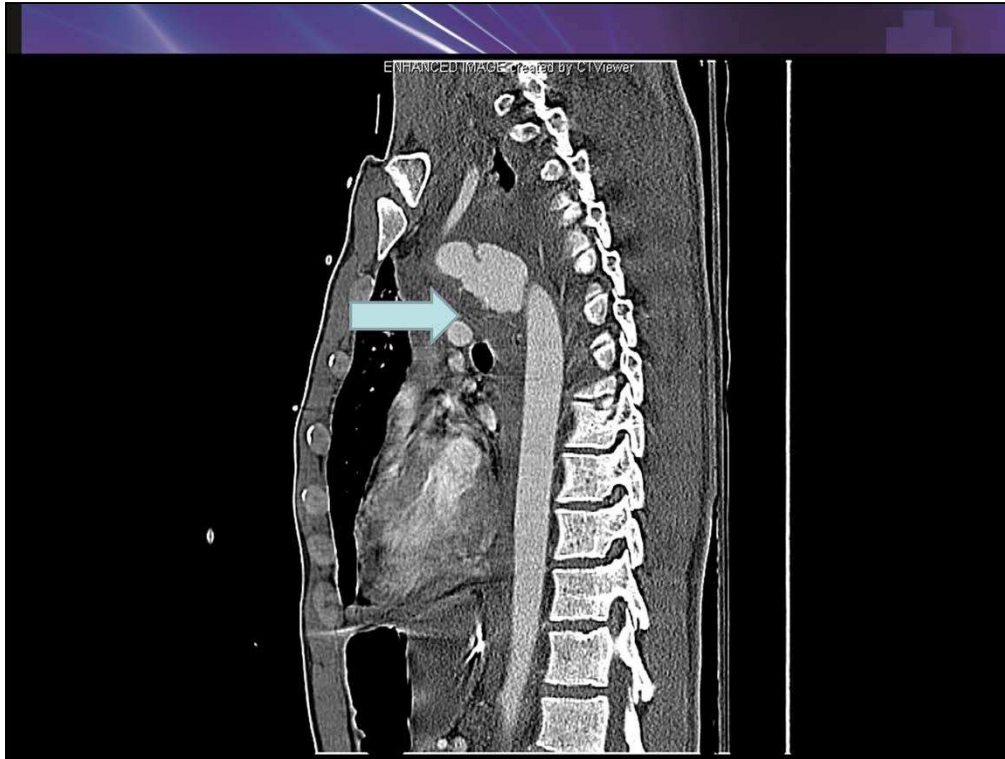

See previous discussion on CTA and Arteriography.

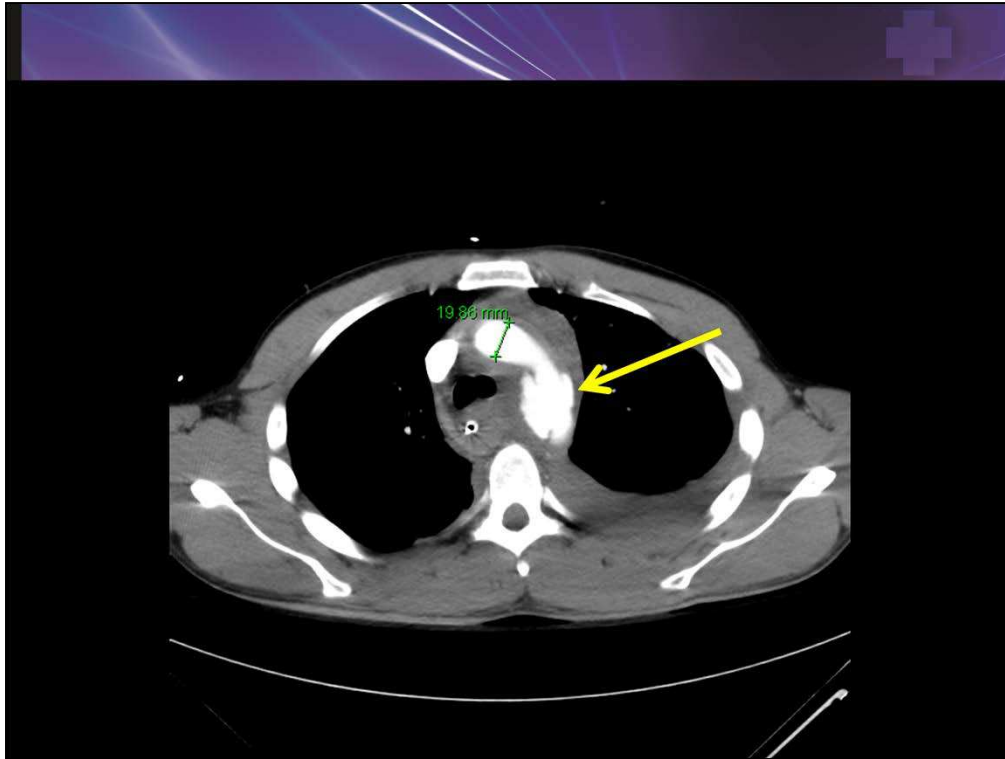
Aortography has been the gold, however, the new generation spiral CT scanners have 100% sensitivity and greater than 99% specificity, thus the use is declining. Helical scanners (when available) have virtually replaced the more invasive arteriography procedure for blunt aortic injuries.

Most authors advocate that positive findings or findings suggestive of an aortic injury be augmented by aortography to more precisely define the location and extent of the injury.

It can provide a more exact delineation of the location and extent of aortic injuries and provides better imaging for injuries of the ascending aorta as well as injuries of the thoracic great vessels.

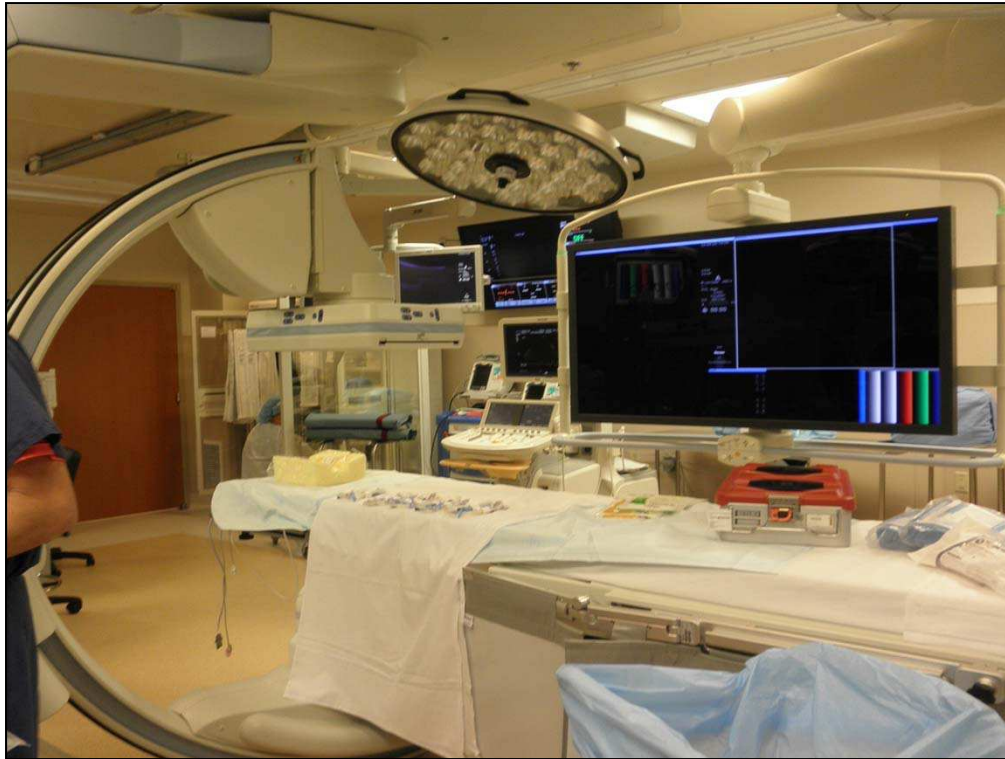

Transected aorta with blush of contrast



25 year old MCC victim. Rapid deceleration injury.

Arrow points to contrast extravasation into mediastinum from aorta transection



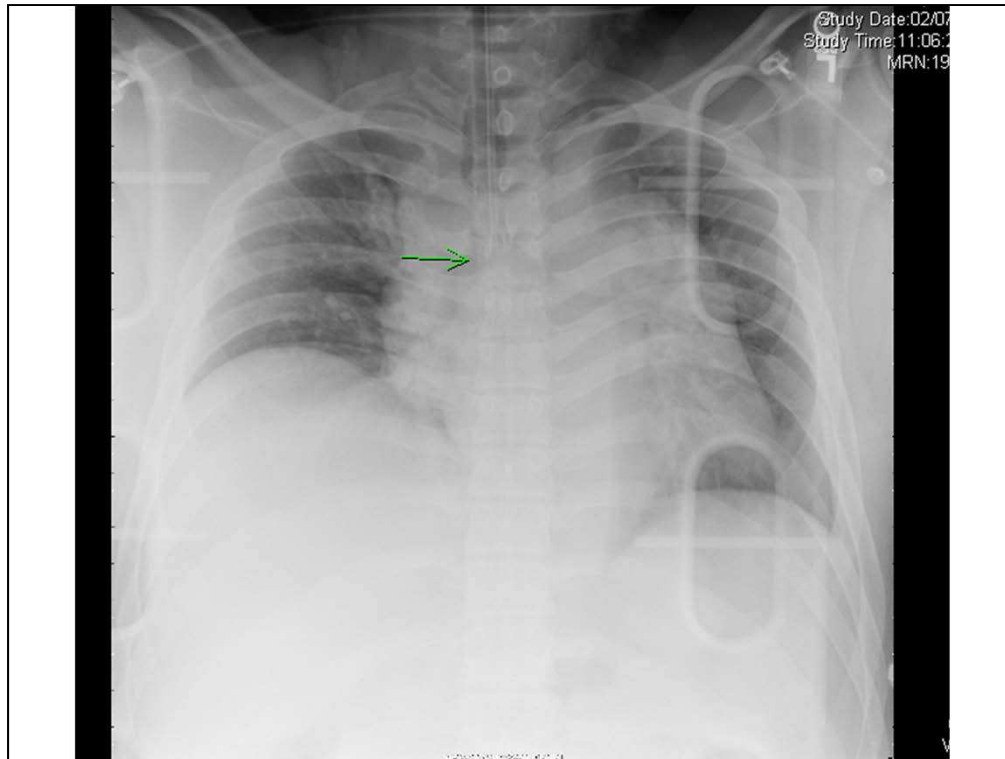
Hybrid OR with all the technology.

Different approaches to treatment depending on location.

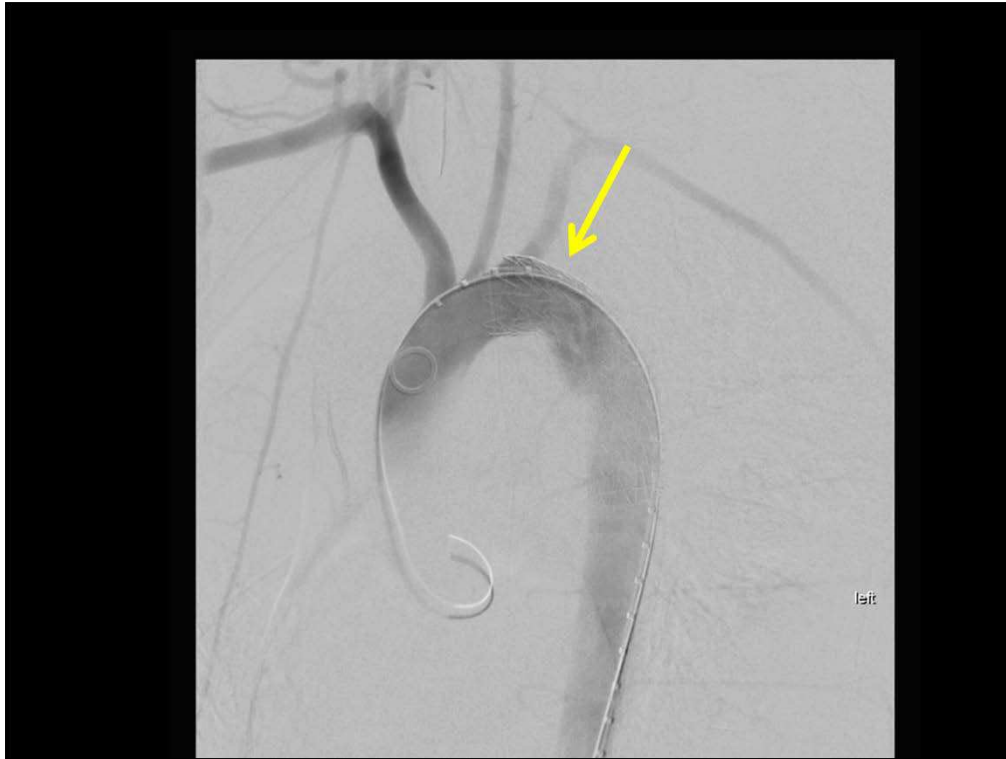- Traditional bypass for repair; newer ELG (endoluminal graft) successful in certain types.
- Planned operative procedures: medical management with Esmolol drip, a short acting beta blocker, to decrease the vessel wall tension and keep patient's BP lower purposefully to buy time to stabilize patient, mobilize proper team, and better prepare for proper procedure

In fact, it is such an important tool in the armamentarium of treatment options, some centers are developing hybrid OR suites that can handle cases combining various specialties, (trauma, ortho, neuro, IR, etc) without having to move the patient.

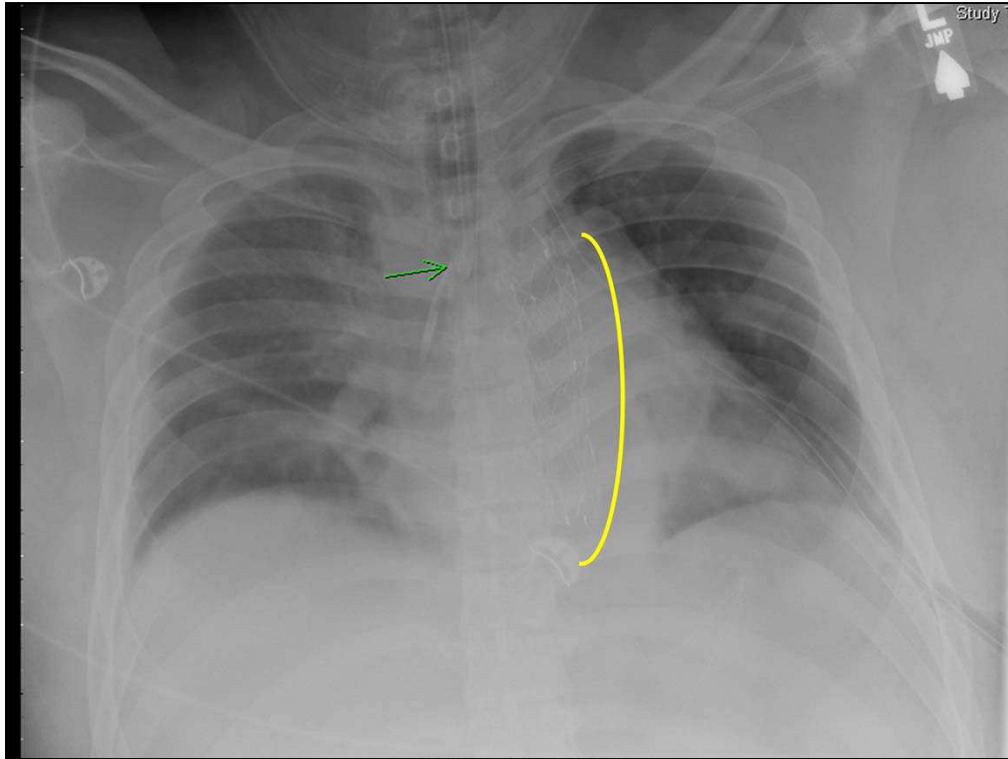
Patient's one stop for OR, Angio, etc. Does not require the patient to be moved. Teams rotate in / out.



Widened mediastinum prior to stent.



In Hybrid OR during procedure with endoluminal graft (ELG) being placed.



With ELG



Actual stent... Very paper thin, almost like filter paper with thin wiring to hold shape.

Blunt Diaphragmatic Injury

- Usually result from high-speed MVC or severe blow to abdomen
- Initial chest x-ray may be normal
- Suggestive findings
 - Abnormal nasogastric tube placement
 - Ipsilateral hemidiaphragm elevation
 - Abdominal visceral herniation



Occurs on left side in 65-80% cases.

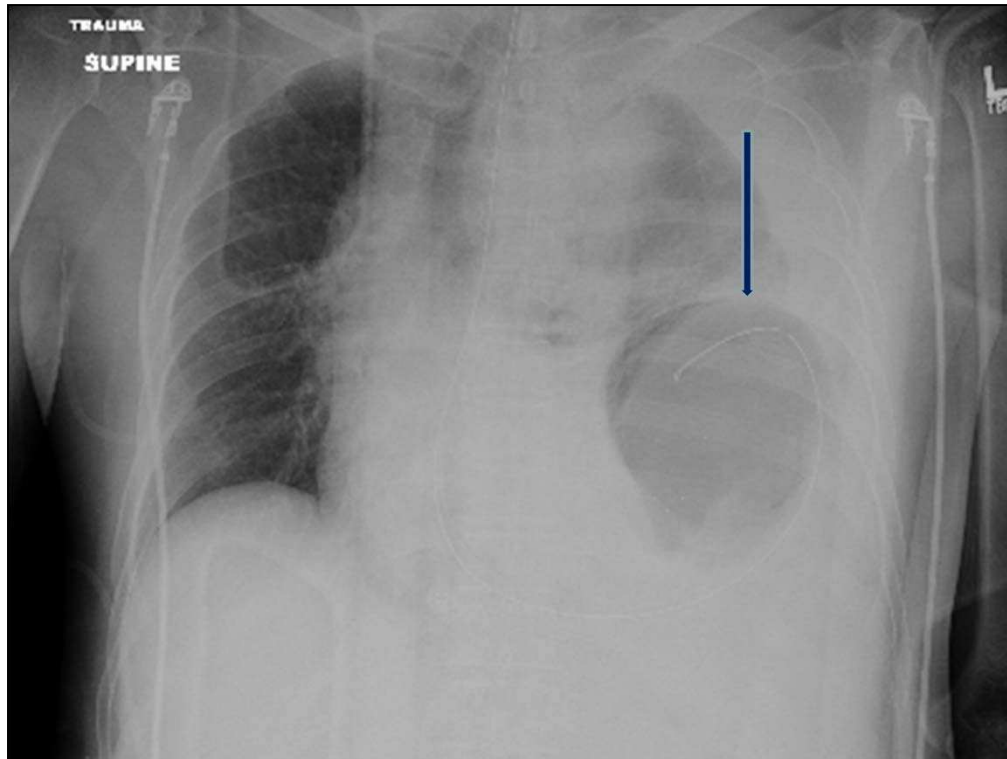
Usually result of high-speed MVC

High incidence of associated injuries

Initial chest x-rays usually normal, especially if patient is on positive pressure ventilation.

Suggestive findings include abnormal position of nasogastric tube, ipsilateral hemidiaphragm elevation, or abdominal visceral herniation into chest.


See further discussion under abdominal presentation.



Note the left chest with gastric tube curled, indicative of a ruptured diaphragm.


Other Injuries

- Subcutaneous emphysema
- Traumatic asphyxia
- Simple pneumothorax
- Hemothorax
- Rib fractures
- Clavicle, scapula, sternal fractures





Next we will review some other types of findings and injuries.

Subcutaneous Emphysema



- Airway injury
- Facial swelling
- Pneumothorax
- Blast injury

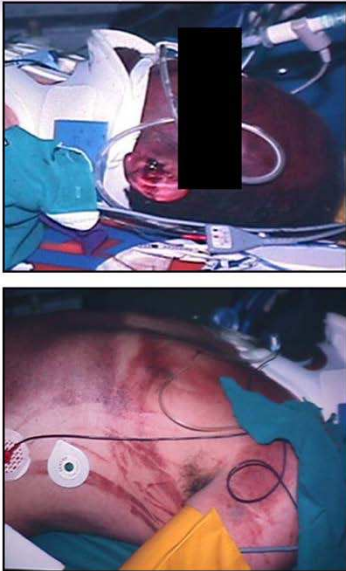



Confirm cause with CT scan

May feel like “rice krispies” under the skin.

Traumatic Asphyxia

- Crushing force to chest
- Cyanosis of head and neck
- Subconjunctival hemorrhage
- Hemotympanum
- Associated injuries





- Clinical constellation from crushing injury
- Cyanosis of head and neck, Subconjunctival hemorrhage, periorbital ecchymosis, and petechiae of head and neck
- Face may appear edematous or moonlike
- Epistaxis and hemotympanum may be present
- History of loss of consciousness, seizures, or blindness may be present
- Neurologic events usually transient, but needs serial neurological exams
- Elevate head of bed 30 degrees to decrease pressure to the head
- Assess for associated thoracic and abdominal injuries
- Surgery may be indicated for associated injuries

<http://emedicine.medscape.com/article/428723-overview#a30>

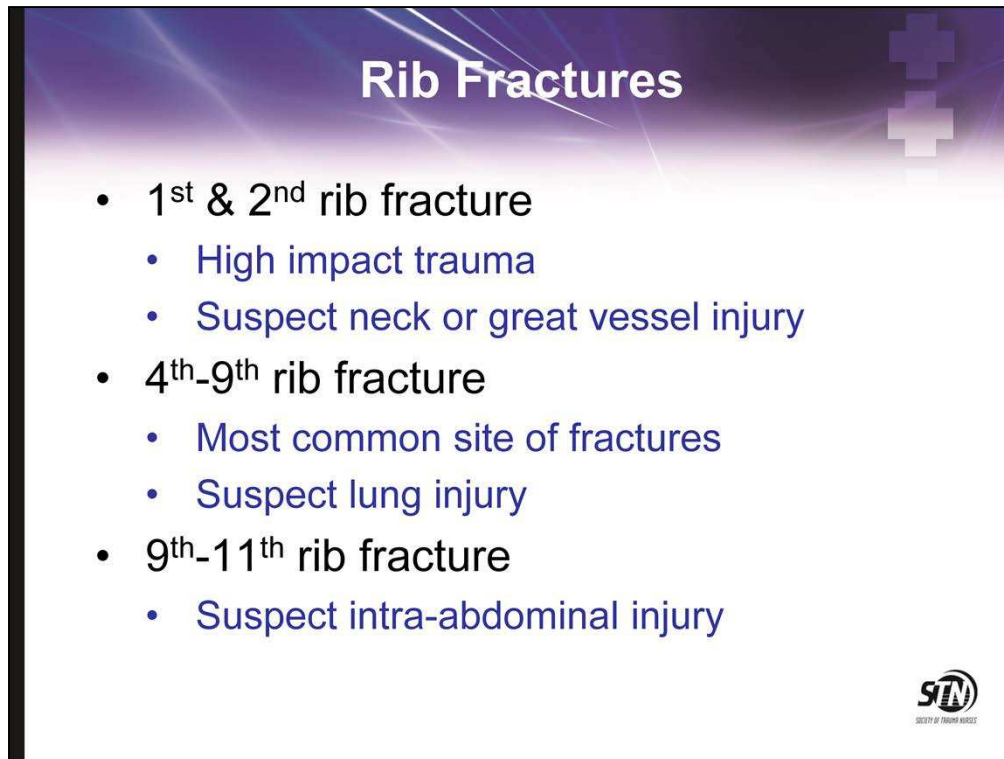
Note the photo.

This middle aged Caucasian male patient was crushed when he fell into a trash compactor.

One can see the venous engorgement as noted in his face (cyanosis)

Hemotympanum of the left ear

Abrasions and contusions on his torso resulting from the prolonged crushing effect and potential for associated injuries.



Pitfall: Do not underestimate pathophysiology of rib fracture and their effects, especially in the older population

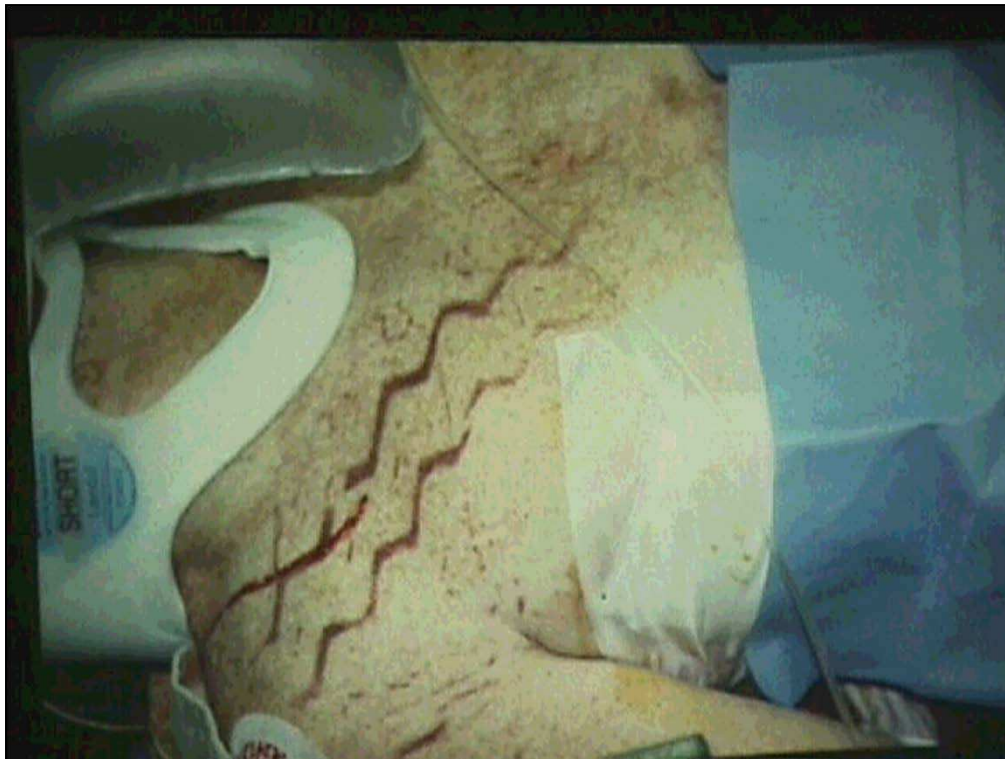Extent of fractures varies with age, young people ribs more elastic and recoil from impact

National Center for Health Statistics: 350,000 people treated for rib fractures in 2010

Most are not admitted so accuracy in numbers is debatable.

Mechanisms: MVC, Fall from heights

- Rib fractures are the most commonly injured structure in the chest, occurring in 2/3 of patients with thoracic trauma.
- Multiple rib fractures cause significant pain. Patients usually report inspiratory chest pain and discomfort
- Ribs 4-10 are most frequently involved.
- Pain causes respiratory compromise, leading to:
 - Reduced pulmonary function
 - Sputum retention
 - Ineffective cough
 - Decreased ventilation leading to hypercapnia and hypoxemia
- Effective analgesia improves gas exchange, pulmonary toilet, LOS, and patient well being.




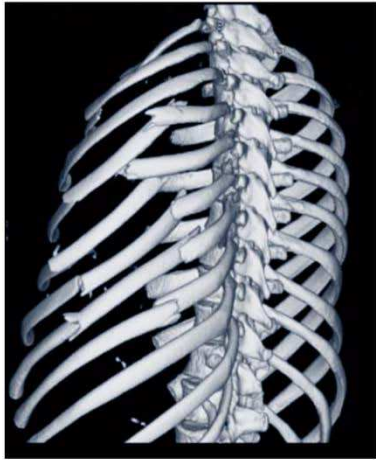
What do you think the mechanism of injury was for this patient? MVC ran over pedestrian

What is the tire marking called? Tattooing

Given the obvious chest injuries from this mechanism and the location of several right sided rib fractures, what other injuries might you anticipate? This patient had severe liver laceration/avulsion.

Clinical Challenges

- Mechanical factors
- Rib fracture motion
- Prolonged pain
- Contracture of fractured segments
- Thoracic volume loss
- Persistent pain



Mechanical factors

- Paradoxical chest wall movement
- Chest wall recoil

Rib fracture motion

- Sharp edges
- Persistent PTX
- Parenchymal injury

Prolonged pain

- Epidural temporary
- Intercostal nerve block
- Prolonged intubation

Contracture of fractured segments

- Thoracic volume loss
- Persistent pain – long term, chronic
 - Mal-unions, non-unions
 - Nerve entrapment
 - Deformed rib ends



Rib Fractures

Triad

- Inspiratory pain
- Shallow respirations
- Retained secretions

Goal of Therapy


- Pain control
- Adequate pulmonary function
- Avoid potential complications



- Upright posterior-anterior (PA) chest x-ray usually all needed to identify fractures
- Most important pathophysiologic insult caused by rib fractures is local pain and chest wall spasms
- Pain results in splinting which leads to hypoventilation
- Inadequate ventilation and cough produces retention of secretions and atelectasis
- Goals of treatment is to relieve pain and maintain pulmonary function
- Interventions: analgesia, coughing/deep breathing, incentive spirometry
- Elderly patient with or more fractures have a 5 times increased mortality and 4 times incidence of pneumonia

Other Injuries

Scapula	Clavicle
<ul style="list-style-type: none">• Uncommon• Clinical signs<ul style="list-style-type: none">• Pain• Edema• Crepitus• Management<ul style="list-style-type: none">• Analgesia• Immobilization followed by PT	<ul style="list-style-type: none">• Common• Clinical signs<ul style="list-style-type: none">• Tenderness• Crepitus• Deformity• Management<ul style="list-style-type: none">• Shoulder immobilizer• ORIF



Scapular Fractures are uncommon but require major force to fracture. Associated injuries are common

Clinical signs: local pain, tenderness, swelling, crepitus

Increase incidence related to use of CT scan

Management: analgesia, immobilization followed by physical therapy, occasionally requires surgery


Clavicle Fractures commonly occur as isolated injury and may be associated with other thoracic injuries.

Clinical signs: tenderness, crepitus, palpable deformity

Initial Management: Figure 8 shoulder immobilizer; non union occurs 20%; ORIF may be needed for severely symptomatic patients

Sternal Fracture

Clinical Manifestations	Management
<ul style="list-style-type: none">• Anterior chest pain• Tenderness• Palpable deformity• Unstable fracture may result in flail chest• ECG changes	<ul style="list-style-type: none">• Cardiac monitoring• Serial ECG to rule out myocardial insult• Echocardiogram• Pain Control



Anterior blunt chest trauma

Classic example is when chest hits steering wheel, direct blow to sternum. Since the addition of airbags, deployment usually prevents us from seeing this type of injury.

Associated injuries include blunt cardiac injury, pulmonary insult, pericardial tamponade, cardiac rupture

Signs include anterior chest pain, tenderness, palpable deformity, unstable fractures may result in flail chest, and ECG changes


Diagnostic-Clinical exam, confirmed by lateral chest radiograph

Management may include:

- Cardiac monitoring
- Serial ECG to rule out myocardial insult
- Echocardiogram
- Pain control

Thoracic Duct Injury

- Uncommon
- Empties into venous system
- Transports 4 liters of chyle per day
- Milky white fluid
 - May be clear if patient NPO
- Chylothorax
 - Chyle in pleural cavity
 - May not occur for several days after injury
 - Nutritional Support



- Rare following blunt trauma
- May be seen in penetrating from laceration of thoracic duct

Thoracic duct as previously reviewed

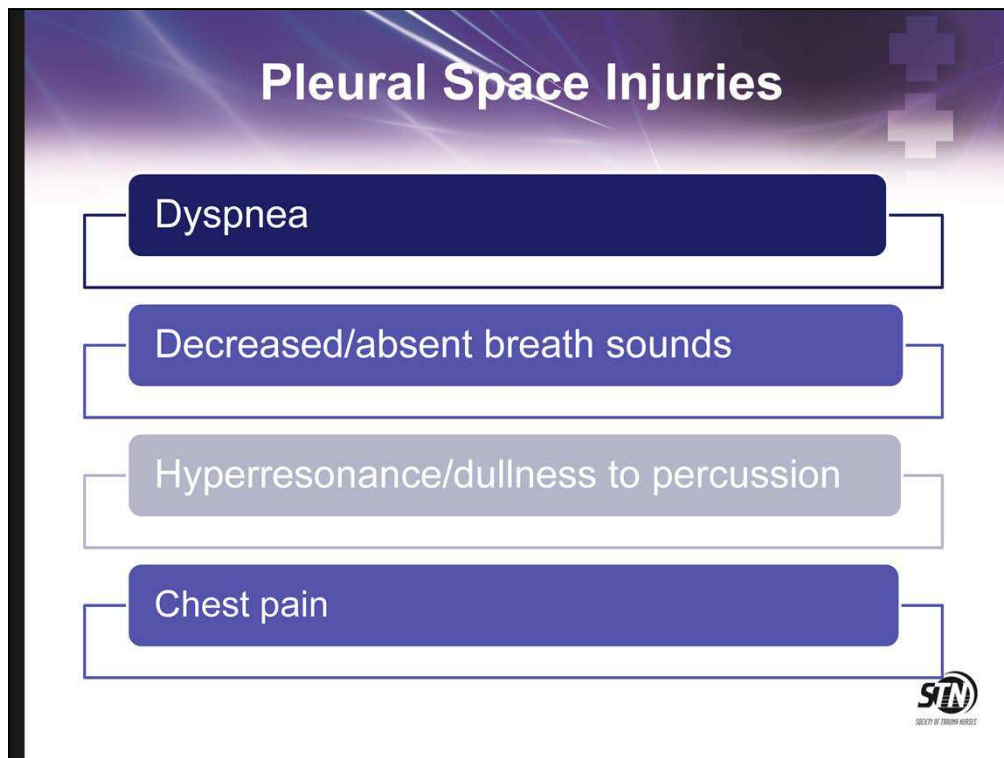
- Thoracic duct is protected posteriorly by spine and anteriorly by mediastinal contents
- Thoracic duct is thin and fibromuscular and can be ruptured anywhere along its length
- Thoracic duct transports about 60% to 70% of ingested fat to blood stream
- Empties into venous system at junction of internal jugular and subclavian veins
- In healthy adults, the thoracic duct transports approximately 4 liters of chyle per day (120 mL/h), rate increases after eating
- Most common mechanism of injury to thoracic duct is sudden hyperextension of spine
- A tear in thoracic duct can be caused by stretching the duct over vertebral bodies or by shearing of duct by right diaphragm
- Injury above 6th thoracic vertebra generally results in left-sided chylothorax
- 20% of traumatic chylothorax associated with spinal fractures
- Chylothorax is accumulation of chyle in pleural cavity
- Chyle is milky white and high in fat and protein
 - color of chyle helps in diagnosis of chylothorax
 - electrolyte content of chyle is similar to serum
- May not occur for several days after injury
- Fluid may be clear if patient had been NPO
- Diagnosis of chylothorax is established by examining pleural fluid
- Triglyceride and chylomicron levels greater than 1.24 mmol/L (110 mg/dL) are diagnostic of chylothorax
- Cultures of fluid are negative for bacteria because of bacteriostatic properties of lymph
- Effusion of large volumes of chyle can be serious respiratory and nutritional problems
- nutritional support is required due to combination of increased metabolic demand due to loss of chyle and hypermetabolism due to original trauma
- Controversy as to how long to try non-operative management before going to surgery
- Early use of VATS to ligate injured duct is showing to be optimal therapy

Pleural Space Injuries

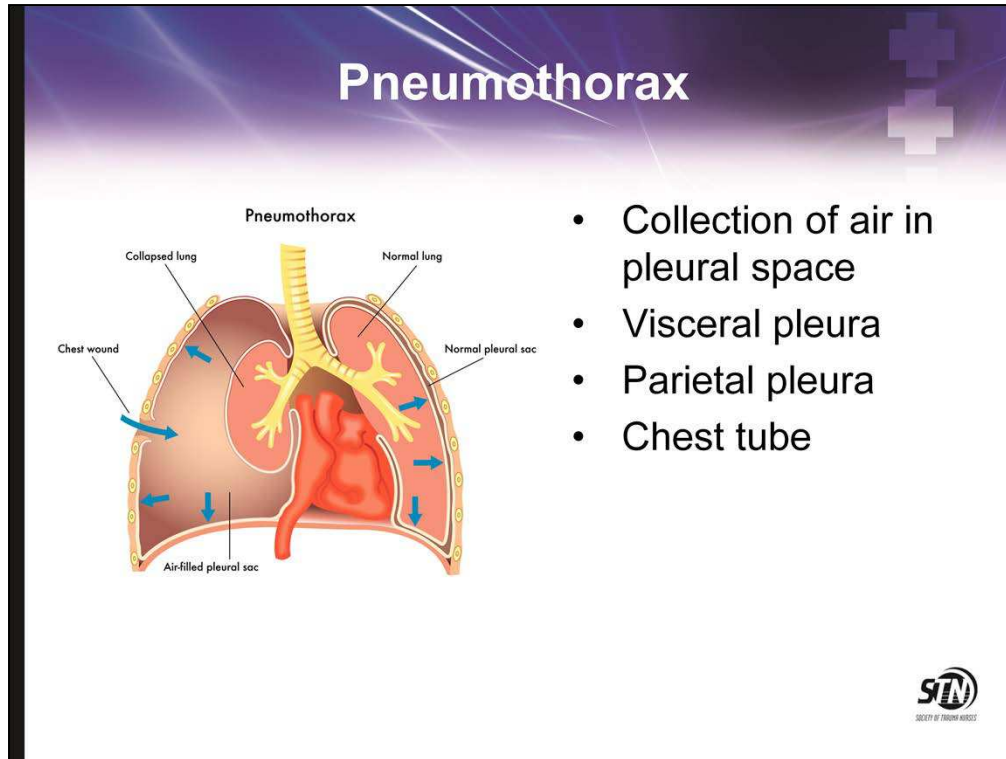
- Accumulation of blood (hemothorax) or air (pneumothorax) between pleural space
- May be unilateral or bilateral
- Classification
 - Small: $\leq 15\%$ of pleural cavity
 - Moderate: 15-60% of pleural cavity
 - Large: $>60\%$ of pleural cavity



Loss of pleural integrity allows air/blood into pleural space resulting in partial collapse of lung due to natural elastic recoil



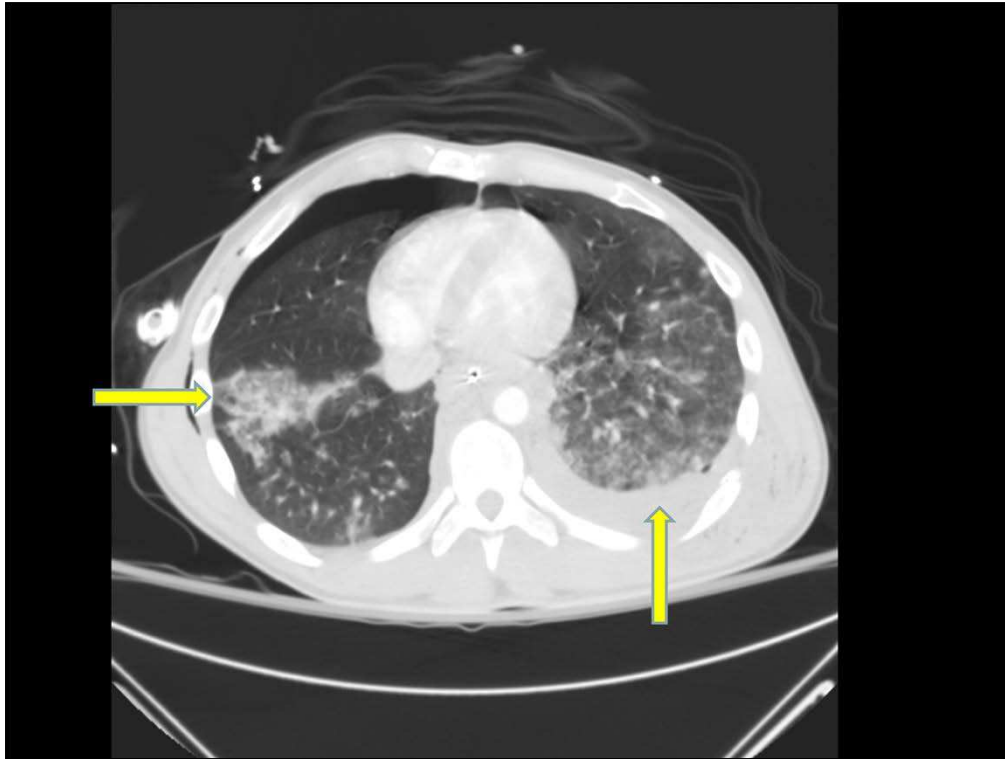
Review the assessment of someone with suspected pneumothorax



Note the photo and point out the pathophysiology of a pneumothorax

Three subtypes of pneumothorax: simple, open, and tension

Chest tube placement is in 4th or 5th intercostal space


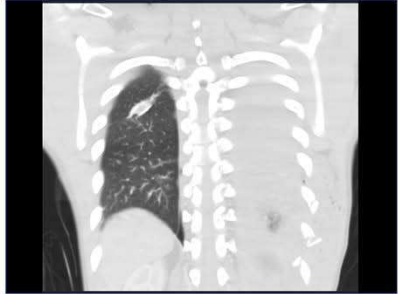


Right pneumothorax; left arrow pulmonary contusion in parenchyma. Right up arrow is hemothorax

Hemothorax

Primary causes

- Lung laceration
- Intercostal vessel laceration
- Internal mammary artery laceration
- Thoracic spine fracture/dislocation




The image is a chest X-ray showing a hemothorax on the left side. The left lung is partially obscured by a large, dense, white area representing accumulated blood in the pleural cavity. The right lung appears normal. The bony structures of the thorax, including the ribs and spine, are visible.

Blood accumulates in pleural cavity
Hemothorax on the left in image

ATLS Manual, pg 93

Pleural Space Management

- Small pneumo/hemothorax may be monitored with serial chest x-rays
 - Usually spontaneously reabsorbs
- Chest tube required for moderate to large pneumo/hemothorax
 - Monitor output for amount and color
 - Monitor air leaks
 - Assess insertion site and connections
- Supplemental oxygen



In the emergency setting, a chest tube is inserted to drain both air and blood
Diaphragm can rise to fourth intercostal space

Fourth or fifth intercostal space, mid-axillary line is safest place

In adults and adolescents: 36-French chest tube should be used to minimize possibility of clotting

Once chest tube inserted, will be sutured in place

Re-expansion of lung should occur over next 24-48 hours

Variety of drainage systems available

3-chamber concept: suction control chamber, water seal chamber, drainage chamber

Chest tube requires about 20 cm of negative pressure

Patients may be placed on supplemental oxygen (nasal prongs) to enhance reabsorption of pneumothorax

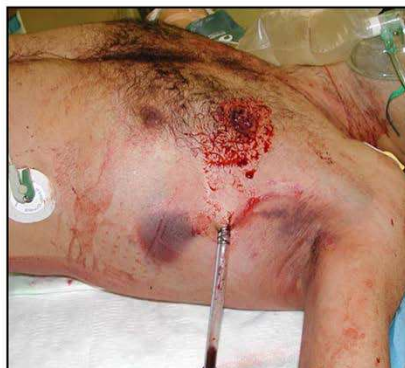Trauma pg 536-538

Trauma, pg 515

Chest Tube Insertion

Complications

- Laceration of intrathoracic &/or abdominal organs
- Pleural infection
- Damage to intercostal nerve, artery, vein
- Intercostal neuritis/neuralgia
- Incorrect tube position
- Persistent PTX



Chest Tube

- Chest x-ray post insertion
- Monitor chest tube output
- Provide amount of suction per physician's order
- Chest tube dressing per hospital protocol
- Evaluate effectiveness of chest tube

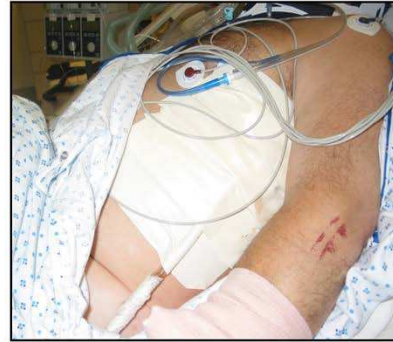


Image: chest tube taped and secured.

- Unless contraindicated, patient with chest tube can be mobilized.
- While chest tube is to suction, mobility may be limited to patient's room, up to chair.
- Once chest tube off of suction, patient should be encouraged to ambulate, keeping device below chest level to prevent back flow of fluid
- Assess patency frequently.

Troubleshooting Chest Tube

- Patient pulls CT out.....
 - Cover w/dressing, call physician immediately
- No Drainage.....
 - Check tubes for kinks, disconnection
 - Do not milk tubing
 - Raise HOB, lower pleurovac
 - Turn to affected side
 - Consider patient's condition



Here's an example of something all nurses may encounter. What do you do?

Pain Management

Various options

- Analgesic agents
- Intercostal nerve blocks
- Local anesthetic
- Epidural analgesia
- Internal rib fixation

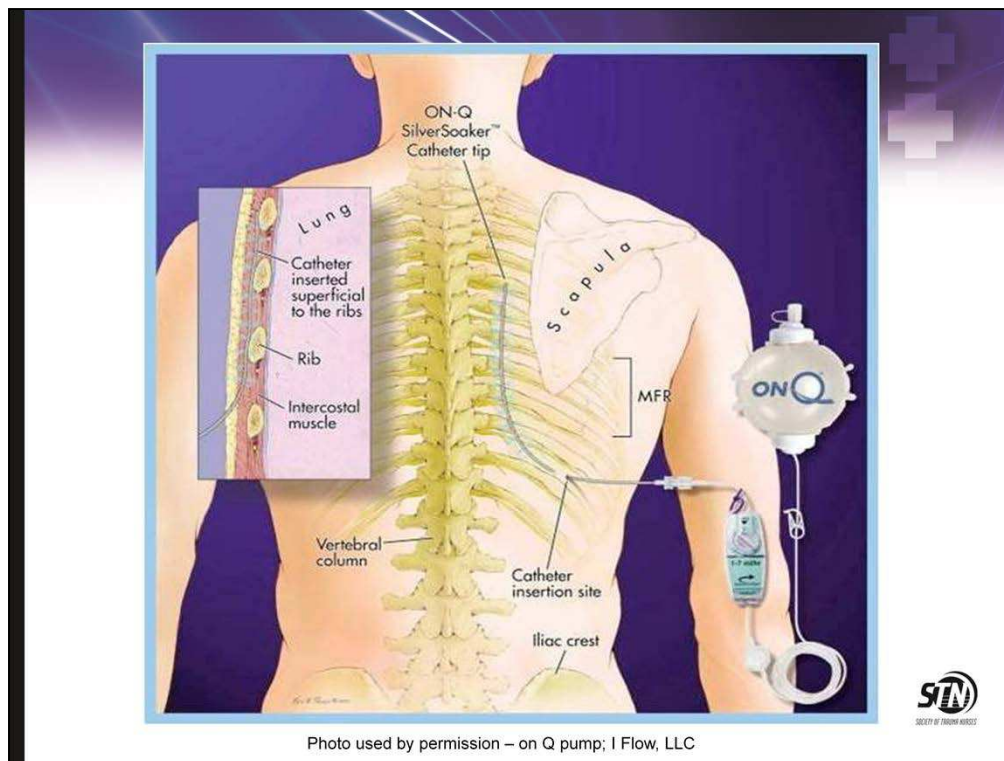


ONQ PainBuster®
Redefining Recovery™

Photo courtesy of on Q pump; I Flow, LLC



Effective pain control is the cornerstone of medical therapy for patients with rib fractures. For most patients, this consists of oral or parenteral analgesic agents. Intercostal nerve blocks may be feasible for those with severe pain who do not have numerous rib fractures. A local anesthetic with a relatively long duration of action (e.g., bupivacaine) can be used. Patients with multiple rib fractures whose pain is difficult to control can be treated with epidural analgesia.



This particular system has been gaining popularity in recent years and has been documented in the literature as being highly effective in controlling pain.

Pain Management Goals

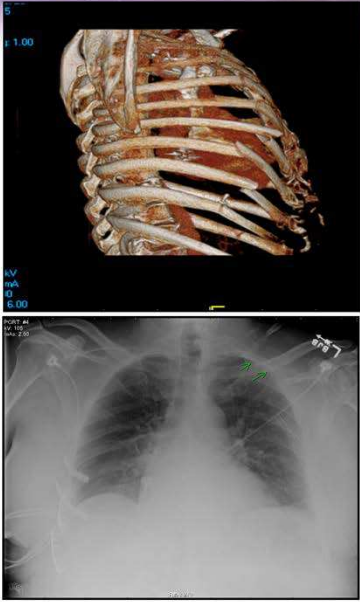
- Decrease opioid use
- Earlier extubation and removal from vent
- Improved gas exchange
- Improvement in patient satisfaction
- Improved length of stay



As noted. By decreasing a patient's pain, only positive things will result in many facets of care.

Operative Fixation

- Reduction in pain
- Ability to reconstruct chest wall
- Restore thoracic volume
- Decreased ventilator days
- Decreased hospital LOS
- Decreased neuralgia



The image block contains two medical images. The top image is a 3D reconstruction of a rib cage, showing several fractures on the right side. The bottom image is a chest X-ray (CXR) showing the same area with surgical plating and wires applied to the right lower ribs. Technical data on the left of the X-ray includes: 5, 1.00, kV, mA, 6.00, PORTAL, 14, 10, 2.0. The STN logo is in the bottom right corner.

Discuss the goals of operative fixation.

Note the 3D reconstruction of rib fractures and then fixation on right lower ribs.

Note the CXR with plating.

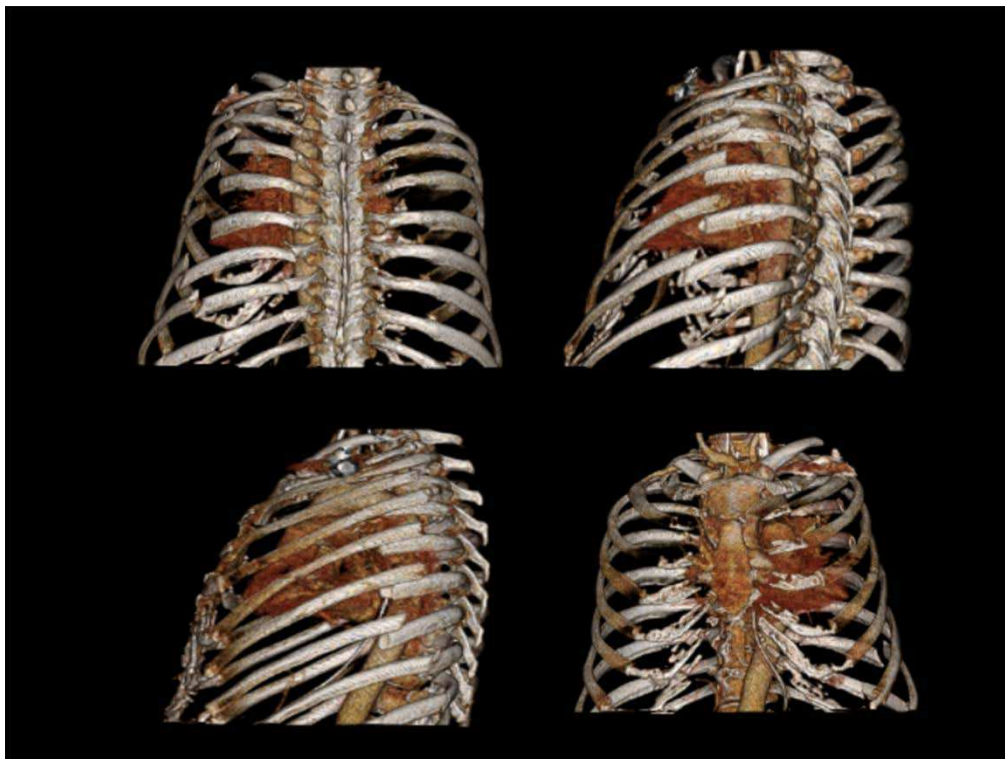
During the past few years, improvement in instrumentation has made this a viable option for select patients.

Case Study

- 60 y o female, +SB driver
- T-boned at high speed on the driver's side
- Major intrusion on left side
- Extrication
- Closed-head injury with SAH
- Multiple left rib fractures (#2-10)
- Left hemopneumothorax
- Multiple pelvic fractures
- Large contusion left flank



Review the case study and subsequent slides.



Different 3 D reconstruction views.

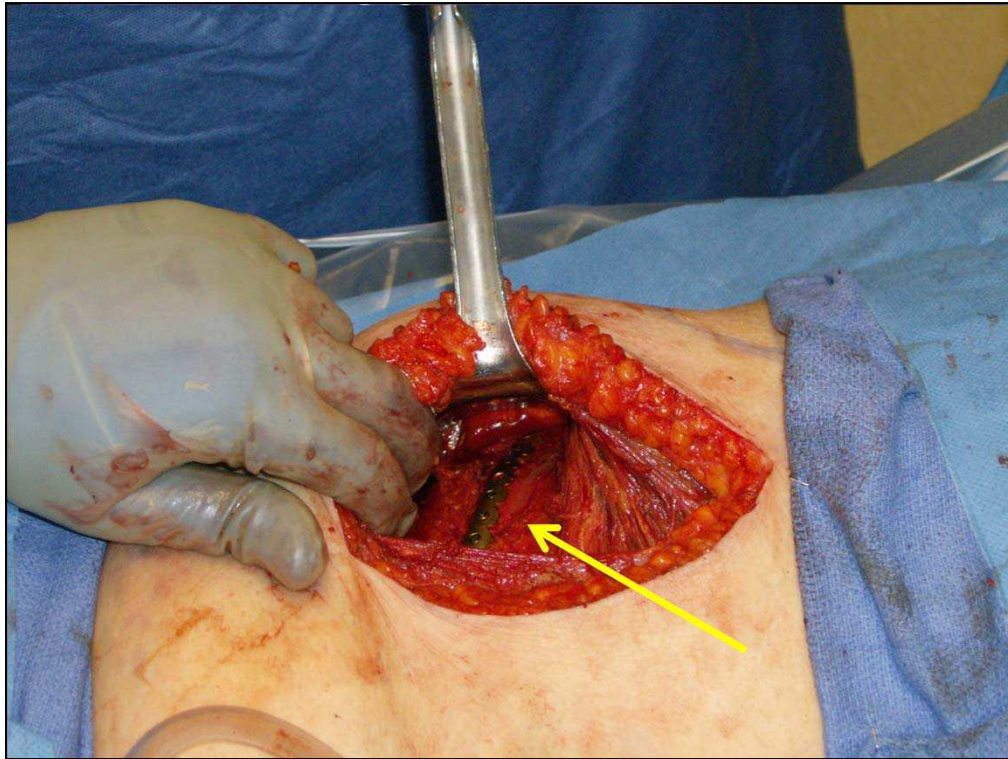
L to R, top to bottom.

Posterior view with left hemopneumothorax and several displaced ribs

Lateral view with same

Lateral view with same and chest tube

Anterior view of same




Rib Fixation Results

ICU

Rib fixation improved

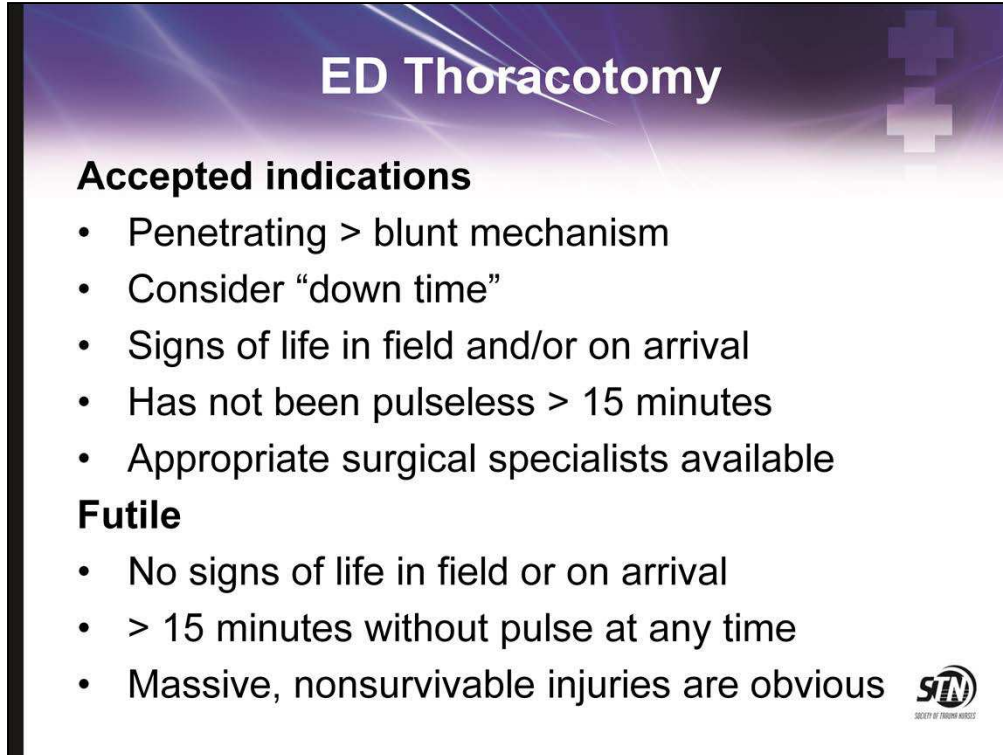
- Pain control
- Bone healing
- Pulmonary function
- Early vent weaning
- Decreased LOS



Study Date: 04/29/2012
Study Time: 12:00:18 PM
MRN: 2013705

STN
SOCIETY OF THORACIC SURGEONS

This patient did very well and was able to be discharged home much sooner than originally anticipated.

A presentation slide titled "ED Thoracotomy" with a purple gradient background and a white cross icon in the top right corner. The slide lists "Accepted indications" and "Futile" scenarios for emergency department thoracotomy. The STN logo is in the bottom right corner.

ED Thoracotomy

Accepted indications

- Penetrating > blunt mechanism
- Consider “down time”
- Signs of life in field and/or on arrival
- Has not been pulseless > 15 minutes
- Appropriate surgical specialists available

Futile

- No signs of life in field or on arrival
- > 15 minutes without pulse at any time
- Massive, nonsurvivable injuries are obvious

STN
SOCIETY OF THORACIC NURSES

Blunt trauma patients who present pulseless and apneic not candidate for emergency (resuscitative) ED thoracotomy (ATLS 2008)

Can accomplish:

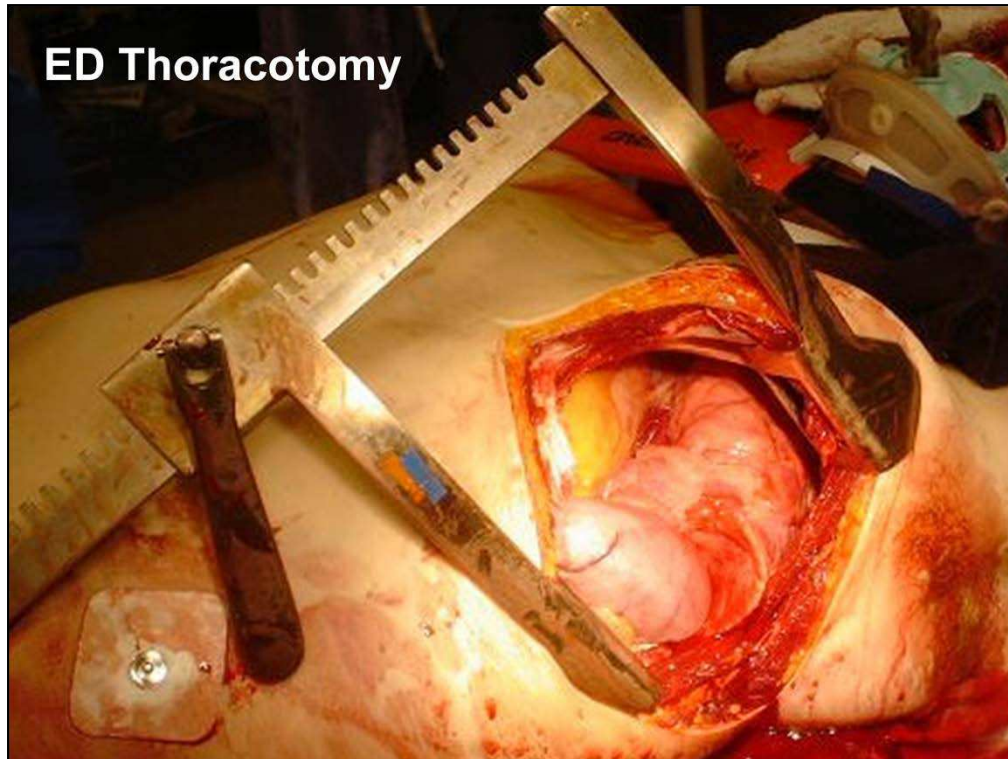
- 1) Remove pericardial blood which caused tamponade
- 2) Open cardiac massage
- 3) Cross-clamping of aorta

Overall survivability rate for penetrating trauma ranges from 4% for gunshot wounds to 17% for stab wounds

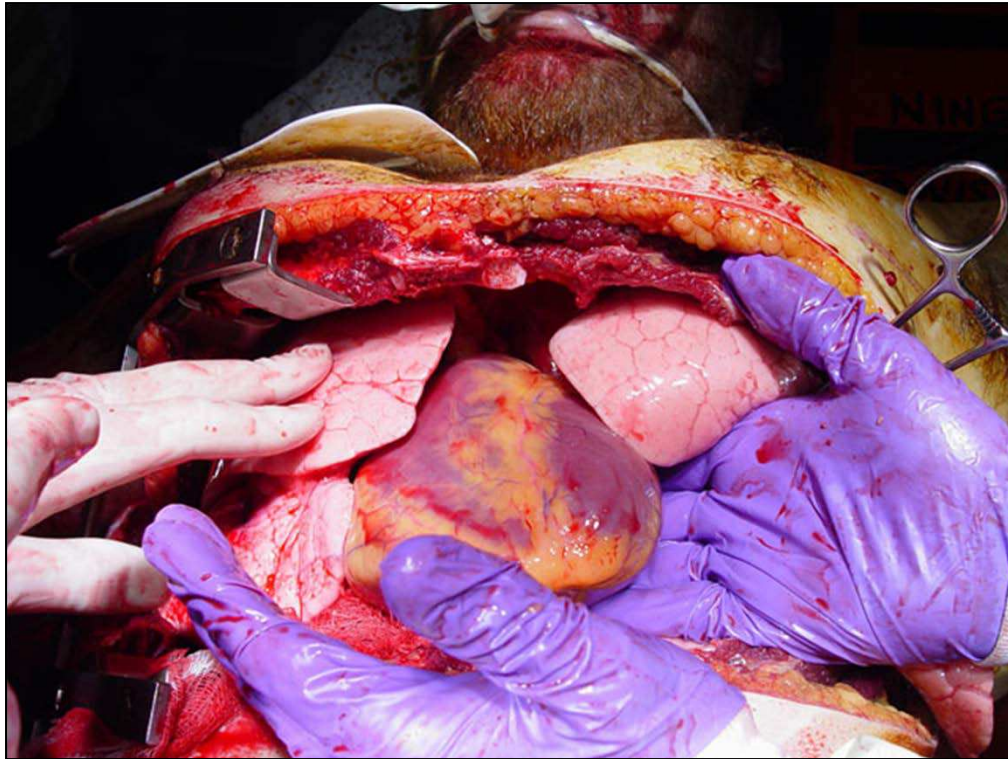
(Rhee PM, Acosta J, Bridgeman A, Wang D, Jordan M, Rich N. Survival after emergency department thoracotomy: review of published data from the past 25 years. *Journal of American College of Surgeons* 2000; 190:288-298)

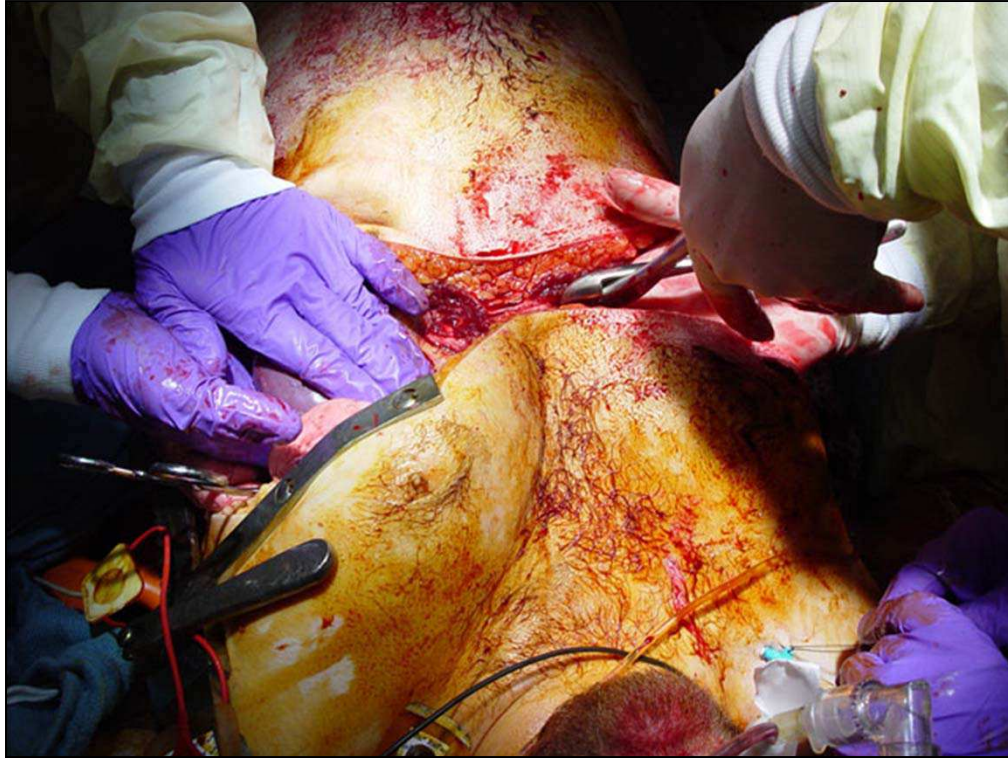
It is generally accepted practice that if a patient has a penetrating trauma to the chest, and had signs of life enroute (provided short transport) and/or signs of life on arrival, EDT may be attempted.

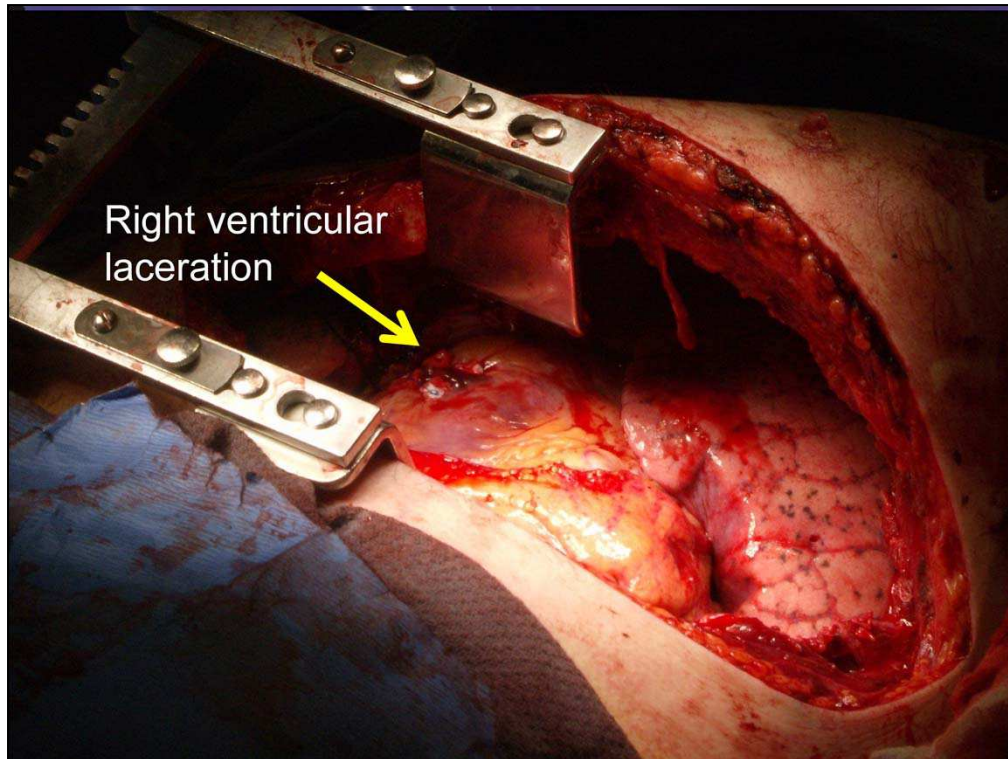
Various procedural positions will be considered by the surgeon depending on the area of the wound, however, most likely an EDT will use an anterior lateral or clam shell incision.



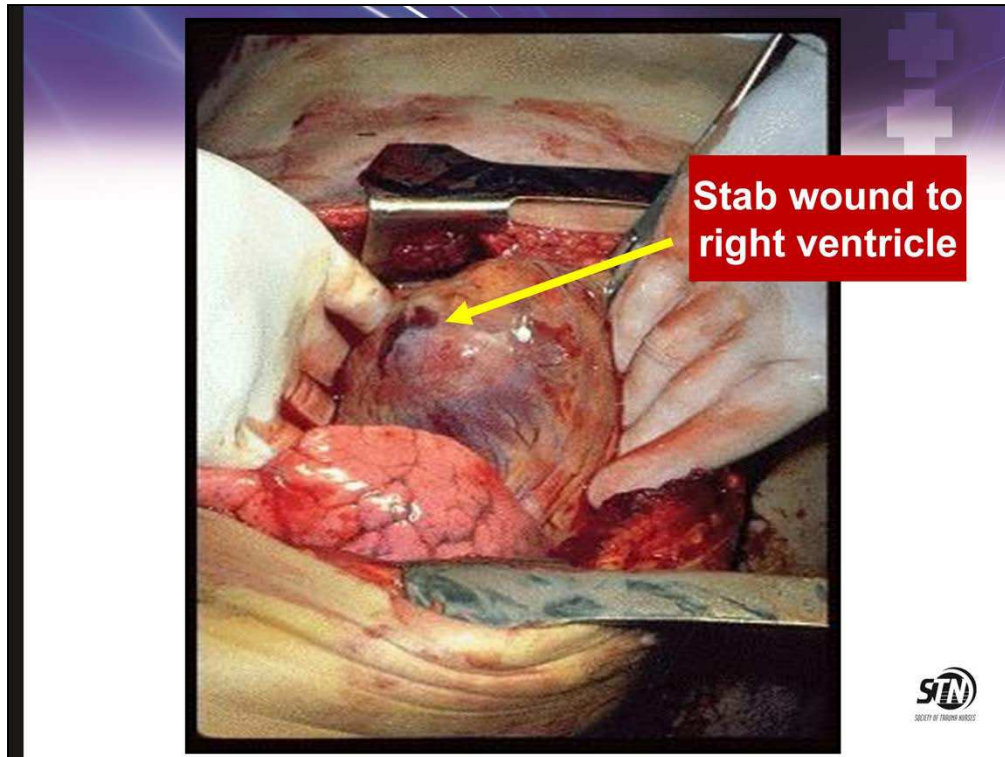
Initial incision for ED thoracotomy







The laceration is visualized



Complications of Chest Trauma

Empyema

- Estimated to occur in 5% of major trauma patients
- Etiologies - inadequately drained pleural space
- Early CT Scan if suspected

Treatment Options

- Chest Tube
- CT guided drainage
- VATS
- Thoracotomy and decortication



- Posttraumatic bacterial empyema is significant source of morbidity following severe chest trauma
- Etiologies include
 - Iatrogenic infection of pleural space following chest tube insertion
 - Direct contamination from penetrating injuries
 - Secondary infection from intra-abdominal injury associated with diaphragmatic disruption
 - Secondary infection from clotted hemothorax
 - Parapneumonic empyema secondary to pneumonia, pulmonary contusion, or ARDS
- Reported incidence ranged from 0-18%, however reasonable estimate is 5% in major trauma patients
- Rate is increasing due to increase of survival rate of critically injured
- The main cause for development of empyema is inadequately drained pleural space
- Empyema should be suspected in chest trauma patient with an unexplained fever, leukocytosis, or respiratory failure
- AP chest x-ray ineffective in delineation of pleural collections
- Early CT scan recommended
- Current treatment
 - Chest tube or CT-guided drainage
 - Chest tube drainage with intrapleural fibrinolytic therapy
 - VATS
 - Open thoracotomy and decortication

Video-Assisted Thoracoscopic Surgery (VATS)

- Usually inserted through existing chest tube site
- Evacuate retained pleural clot
- Used alone or with mini-thoracotomy
- Avoids long-term morbidities associated with traditional thoracotomies



VATS came into widespread use beginning in the early 1990s


It is a type of thoracic surgery performed using a small video camera that is introduced into the patient's chest via a scope, similarly as a laparoscope is inserted into the abdomen.

The great advantage of VATS over sternotomy or thoracotomy is avoidance of muscle division and bone fractures that allows for diminished duration and intensity of pain and a shorter time to return to full activity.

- Useful for:
 - Repair small diaphragm injuries
 - Assessment of continued hemorrhage or air leaks
 - Control intercostal vessel bleeding
 - Evacuation of retained pleural clot (Main use)
- Usually inserted through existing chest tube site after removal of tube
- Can be used alone or with a mini-thoracotomy

Complications of Chest Trauma

Persistent Air Leak <ul style="list-style-type: none">• Common initially• Chest tube placement• Bronchoscopy to rule out tracheobronchial injury	Pneumatocele <ul style="list-style-type: none">• Air collection in lung parenchyma• Usually resolves following weaning from ventilator• May need CT guided drainage
---	--

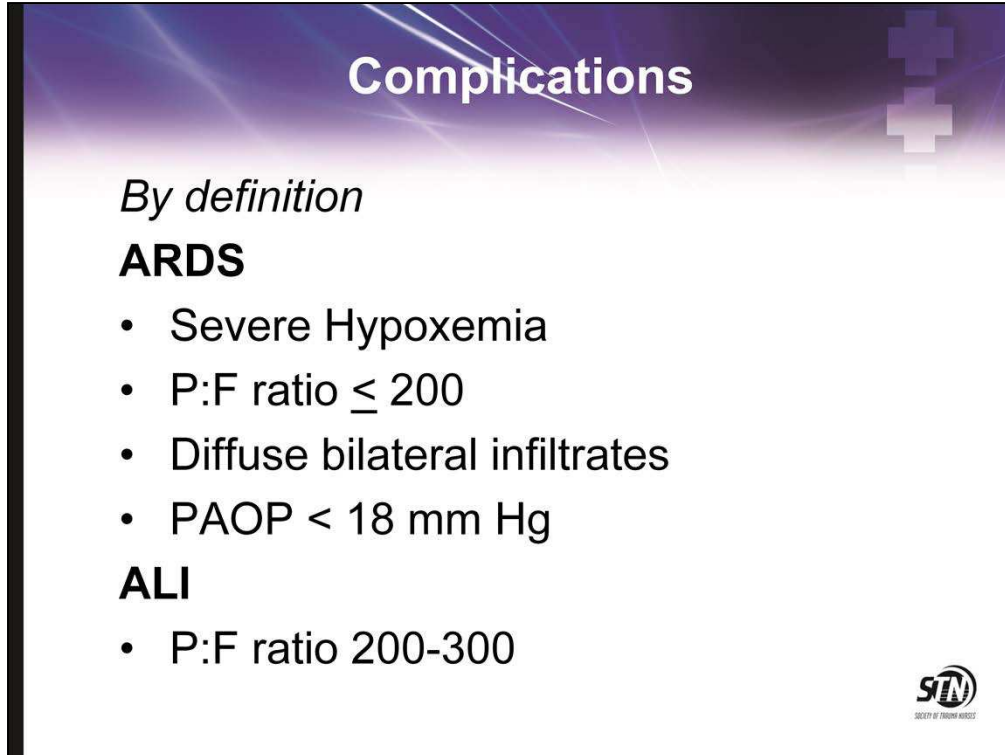


Air Leak

- Air leaks common following chest trauma
- Usually only request chest tube for treatment
- Large air leak mandates urgent bronchoscopy to rule out tracheo-bronchial injury
- May also be observed if chest tube is not positioned correctly or with a large pulmonary laceration
- Complete lung expansion is goal of therapy

Pneumatocele

- Posttraumatic cysts uncommon following chest trauma
- CT scan to diagnose
- Air disruption may lead to air collection within lung parenchyma that does not connect with pleural space
- Seen more frequently with patients who have severe chest trauma and required prolonged ventilatory support
- Most lesions resolve following weaning from ventilator
- If lesions continue to expand or if become infected, may require CT guided drainage



Complications


By definition

ARDS

- Severe Hypoxemia
- P:F ratio ≤ 200
- Diffuse bilateral infiltrates
- PAOP < 18 mm Hg

ALI

- P:F ratio 200-300

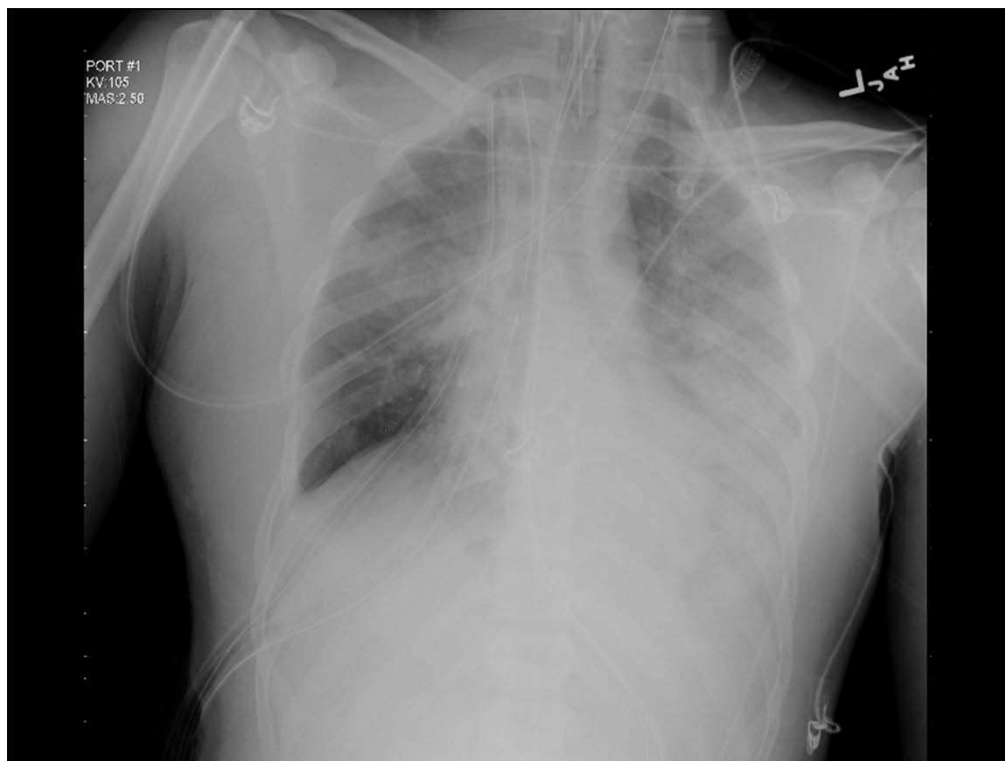


ARDS = Adult Respiratory Distress Syndrome

ALI = Acute Lung Injury

Can be caused by chest trauma, fluid overload (resuscitation)

Aspiration of gastric contents



ARDS

Nursing Considerations

- Monitor the ABCs continuously
- Identify and treat life-threatening injuries during primary survey
- Maintain heightened awareness of potential injuries
- Understand potential complications and be vigilant in observing for them



- In summary, nursing considerations revolve around prompt assessment and reassessment to ensure the patient's condition does not deteriorate.
- The ABCs are of utmost importance as many injuries are life threatening or have the potential to be life threatening, especially if missed.
- Maintaining a high index of suspicion in consideration of the mechanism of injury and all the thoracic structures that have potential for injury is important.
- Having a heightened awareness will allow an astute care giver to promptly intervene in situations that might otherwise go unnoticed.
- Understanding some of the potential complications / sequelae will also allow for increased monitoring

Summary - Keep It Simple

- Chest x-ray identifies majority of blunt thoracic trauma
- No medical intervention or a well-placed chest tube adequately treats 85% of chest trauma
- Maintain high rate of suspicion
- Aggressive pulmonary toilet
- Pain Management



Thoracic trauma continues to produce some of the most challenging and deadly injuries seen. All intrathoracic organs play a vital role in normal physiology and maintaining stability.

Unrecognized injuries (and those untreated) may result in death within minutes from shock, hypoxia, etc.

The mechanism of injury may provide guidance as to potential injuries.

Maintaining an adequate airway with ventilation is key.

Clinical exam is important.

CXR is often the only study required early on.

A chest tube treats the majority of both blunt and penetrating traumatic injuries.

Pain control is essential in preventing complications such as pulmonary atelectasis, pneumonia, and respiratory issues.